

# Coronectomies: assessment and treatment planning

S. Bhola\*<sup>1</sup> and A. Pellatt<sup>1</sup>

## Key points

Educates clinicians on the indications for coronectomy.

Discusses the consent procedure, as well as the indications for referral.

Discusses the clinical and radiographic justification for coronectomy procedures.

Coronectomy procedures are widely carried out in secondary care, involving the removal of the dental crown, while retaining the roots *in situ*. This paper defines and explains the rationale behind coronectomy. It also seeks to review the indications for referral of wisdom teeth, and how to identify high-risk wisdom teeth radiographically using two- and three-dimensional imaging. Using this information, this article aims to provide the practitioner with information on short- and long-term management of high-risk wisdom teeth and discusses coronectomy versus extraction. It also discusses the complications of coronectomy and the importance of adequate consent.

## Introduction

Removal of lower third molars is a commonly practiced procedure in oral and maxillofacial surgery departments in primary or secondary care.<sup>1</sup> Extraction of lower third molars carries a risk to the inferior alveolar nerve (IAN), from 0.4% to 8.4%.<sup>2,3</sup> This may be increased in 'high-risk' teeth. With the increasing use of cone beam computed tomography (CBCT), the relationship of the IAN, a mixed nerve, can now be accurately ascertained from its roots.<sup>4,5</sup>

A coronectomy procedure involves the removal of the dental crown of a tooth while leaving the roots *in situ*, classically practised with lower wisdom teeth. The main aim of the procedure is to reduce the risk of damage to the inferior alveolar nerve for teeth with roots in close proximity.<sup>2,4,6-10</sup>

## Assessment of lower third molars

Not all wisdom teeth require removal. Those that are asymptomatic, and causing no

damage to their neighbours, may be left well alone. If symptomatic or causing insidious damage to adjacent teeth they may be candidates for extraction or coronectomy (see Box 1 for NICE guidelines for extraction of third molars).<sup>11</sup> Mandibular third molars must be reviewed on a case by case basis and assessed both clinically and radiographically and before deciding on a definitive treatment plan, a number of factors must be considered. Impacted third molar teeth are in close proximity to the lingual, inferior alveolar, mylohyoid, and buccal nerves, but usually paraesthesia relates to damage to the IAN or lingual nerves.<sup>12</sup> Figure 1 demonstrates simplified anatomy of the mandible, and the third molar region. Before any procedures are carried out, dental and patient factors need to be considered (shown in Table 1).<sup>4</sup>

## Proximity to the inferior alveolar nerve

The roots of the lower third molars may show the following characteristics radiographically if in close proximity to the nerve:<sup>4,12</sup>

- Narrowing of the roots
- Curving of roots
- Overlapping of root
- Darkening of the roots, or apical radiolucencies
- This is shown diagrammatically in Figure 2.

Those teeth identified as being high risk on plain film (for example, and orthopantomogram) may be further assessed using a cone beam CT (CBCT). A CBCT allows the clinician to visualise the high-risk lower molar tooth in all fields of view in high quality. However, although there has been evidence to show that cone beam images do not affect the sensitivity or specificity for predicting ID nerve damage, they can be useful in aiding surgical planning, and reducing the risk parameters for when the roots of lower third molars are in close proximity to the IAN.<sup>13</sup> This may in turn affect the surgical approach – the use of CBCT is explored later in this paper.

## Consent for coronectomy procedures: risks and complications

As for any dental or surgical procedure, informed consent is required before treatment can progress. The process of informed consent involves the communication of the potential risks and benefits to the patient, who may then voluntarily give permission to the clinician to carry out the defined procedure (where the patient has capacity). The consent process for coronectomy procedures is very similar to that of extraction of mandibular third molars, with some exceptions:<sup>14</sup>

- There may be a need to extract the tooth if the roots are seen to be mobile during the procedure (9–38%)<sup>14</sup>

<sup>1</sup>Dental Core Trainee, Oral and Maxillofacial Surgery, Bristol Dental Hospital, Lower Maudlin Street, BS1 2LX  
\*Correspondence to: Surina Bhola  
Email: surina.bhola@hotmail.com

Refereed Paper. Accepted 3 May 2018  
DOI: 10.1038/sj.bdj.2018.535

- The residual roots may migrate and erupt through the gingivae over time, and need to be extracted eventually, the idea being that the secondary procedure is of lower risk, as it is further away from the nerve. Pogrel *et al.* noted approximately 30% of coronectomised roots migrating over a 6-month period,<sup>7</sup> but some case reports have noted eruption up to ten years following the procedure<sup>15</sup>
- Alveolar osteitis: Leung and Cheung discovered the incidence of pain and dry socket to be lower in coronectomised patients compared to extraction patients, but there were no statistical differences in both groups.<sup>2,3</sup> Renton reported no difference in incidence, which was approximately 5%<sup>14</sup>
- Pain: Renton *et al.*<sup>14</sup> postulated that coronectomised patients may experience less pain compared to extraction patients, possibly due to less bone removal, but further research is required
- Failed coronectomy: this could be due to operator error, or ‘enamel lipping’. All enamel should be removed, as it can serve as a nidus for infection.<sup>1,16</sup>

**Radiographic examination**

A plain film radiograph is a two-dimensional representation of a three-dimensional object.<sup>17</sup> However, if a plain film classically displays the following radiographic signs, it may indicate the need to consider a coronectomy procedure, as opposed to an extraction:<sup>5,12,14</sup>

- Deviation of ‘tram lines’, or interruption of the white lines representing the inferior dental canal
- Darkening of the roots
- Deflection or sudden narrowing of the roots of the lower third molar
- Narrowing of one or both of the white lines representing the ID canal
- Periapical radiolucency of the lower wisdom tooth
- Curving of the roots
- Loss of ID canal cortex (>3 mm)
- Loss or interruption of the lamina dura of the third molar.<sup>18</sup>

Rood and Shehab postulated that only three of the factors mentioned above were seen to be significantly related to IAN damage, these being diversion of the canal, darkening of the root, and interruption of the white line of the ID canal.<sup>5</sup>

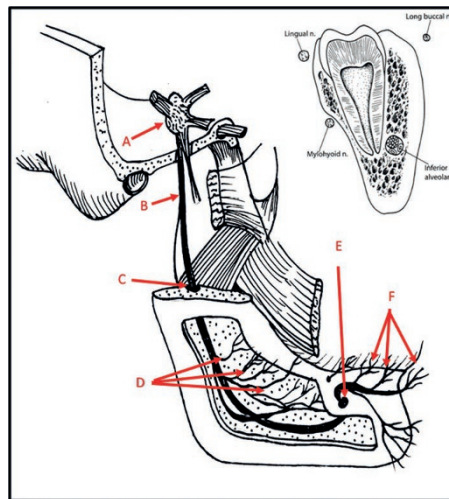
**How to assess a CBCT?**

When any of these are visible on the two-dimensional image, and the tooth is deemed

higher risk, a CBCT scan can be used to assess the 3D anatomy. If this shows that the IAN is in close proximity then coronectomy is a viable treatment option. However, this is something

**Box 1 NICE clinical indications for removal of wisdom teeth**

- Non-treatable pulpal and/or periapical pathology
- Cellulitis, abscess and osteomyelitis
- Internal/external resorption of the tooth or adjacent teeth
- Fracture of tooth
- Disease of follicle including cyst/tumour
- Tooth/teeth impending surgery or reconstructive jaw surgery, and when a tooth is involved in or within the field of tumour resection
- A first episode of pericoronitis, unless particularly severe, should not be considered an indication for surgery. Second or subsequent episodes should be considered the appropriate indication for surgery.



**Fig. 1 Diagrammatic representation of the anatomy of the inferior alveolar nerve. A) Trigeminal nerve ganglion; B) Mandibular branch of the trigeminal nerve; C) Inferior alveolar nerve (IAN); D) Accessory branches of IAN; E) Mental foramen; F) Incisive branches of mental nerve. Reproduced from *Dental Update* (ISSN 0305-5,000) with permission from George Warman Publications (UK) Ltd**

**Table 1 Criteria to assess teeth for coronectomy**

Patient factors		Dental factors	
Medical history	Immunocompromised patients are at greater risk of infection, and therefore leaving roots behind may trigger a foreign body reaction Recent myocardial infarction Diabetes High risk of bleeding	Apical pathology	Coronectomy is contraindicated where cystic formations are present around the roots, or where an apical area associated inflammatory changes are present
		Mobility	Mobile teeth do not qualify for coronectomy, as they act as a foreign body and source of infection
		Proximity to IAN	Close association to the IDN is an indication for coronectomy
		Root anatomy	Curved, divergent, long or dilacerated roots are signs of a complicated extraction. In the absence of infection coronectomy may be preferred.

which is best carried in secondary care or with specialists in primary care. Again, clinicians can read the report of the scan to deduce this if there is any difficulty. Significant high-risk signs include:

- Perforation of the tooth root by the ID canal – the classic ‘polo mint’ appearance
- Narrowing of the ID canal
- Direct contact or flattening of the nerve by the molar root
- Decortication of the bone
- A lingual course of the nerve with/without perforation of the cortical plate
- Intraposition of the nerve.<sup>18,19</sup>

Clinicians should refer to the SEDENTEXT Guidelines, when looking at criteria for CBCT.<sup>20</sup> There have been multiple clinical studies about the use of CBCT for pre-surgical assessment of impacted third molars.<sup>21–29</sup> The SEDENTEXT guidelines have postulated that CBCT can offer advantages for surgical planning, and the position of the IAN and the roots of the third molar but should not be used routinely for all pre-surgical third molar assessments.

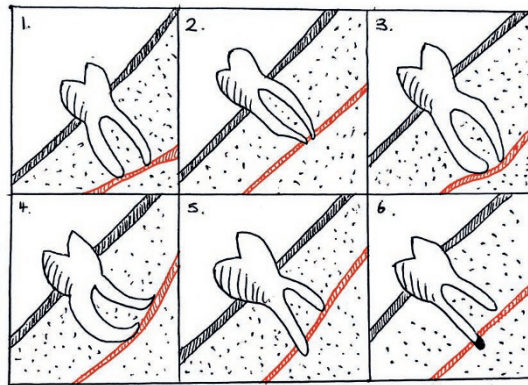
Figure 3 an example of a high-risk wisdom tooth, the image taken using computer tomography.

A summary of the SEDENTEXT criteria is shown in Box 2.

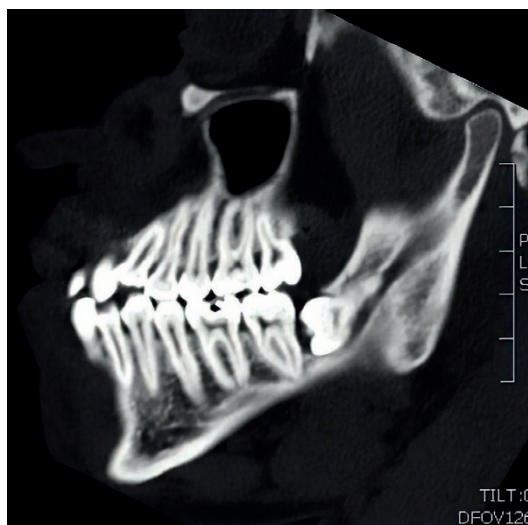
## Tips for the GDP

If there is any doubt about the lower third molar, the GDP can attempt a periapical radiograph of the area. However, in many cases, the patient may not tolerate a film holder posteriorly, especially if impacted, in which case, an OPG is advisable. If there are any radiographic signs or doubt about the lower third molar, the GDP should refer through to the specialist oral surgery service for further investigation. If taking an OPG in primary care, it is imperative that the OPG is of good quality – sending a digital copy which cannot be tampered with is preferable, which may avoid the need to re-expose the patient.

In addition, GDPs may follow up patients in practice who have had coronectomy or those who may have post-operative sequelae such as dry socket and inflammation, which the dentist can manage conservatively. In the long term, the GDP may notice migration of the root through the gingivae. A second procedure is necessary to remove the migrating roots.



**Fig. 2** Diagrammatic representation of the roots of ‘high risk’ molars and relationships to the inferior alveolar nerve: 1) Narrowing of the ID canal; 2) Narrowing of the roots; 3) Deviation of the ID canal; 4) Curving of the roots; 5) Overlap of roots; 6) Darkening/periapical area of the roots



**Fig. 3** A sagittal view of a CT scan showing a horizontally impacted 38, which is in close proximity to the IAN. Courtesy of Michael Millwaters

### Box 2 Summary of CBCT recommendations (SEDENTEXT) (full guidelines can be found at [http://www.sedentext.eu/files/radiation\\_protection\\_172.pdf](http://www.sedentext.eu/files/radiation_protection_172.pdf))

- All CBCT examinations must be justified on an individual basis by demonstrating that the potential benefits to the patients outweigh the potential risks
- CBCT examinations should potentially add new information to aid the patient’s management
- A record of the justification process must be maintained for each patient.
- CBCT should not be selected unless a history and clinical examination have been performed. ‘Routine’ or ‘screening’ imaging is unacceptable practice
- When referring a patient for a CBCT examination, the referring dentist must supply sufficient clinical information (patient history and results of examination) to allow the CBCT
- Practitioner to perform the justification process
- For the localised assessment of an impacted tooth (including consideration of resorption of an adjacent tooth) where the current imaging method of choice is MSCT, CBCT may be preferred because of reduced radiation dose
- CBCT may be indicated for the localised assessment of an impacted tooth (including consideration of resorption of an adjacent tooth) where the current imaging method of choice is conventional dental radiography and when the information cannot be obtained adequately by lower dose conventional (traditional) radiography
- For the localised assessment of an impacted tooth (including consideration of resorption of an adjacent tooth), the smallest volume size compatible with the situation should be selected because of reduced radiation dose.
- Where conventional radiographs suggest a direct inter-relationship between a mandibular third molar and the mandibular canal, and when a decision to perform surgical removal has been made, CBCT may be indicated
- It is essential that a qualified expert is consulted over the installation and use of CBCT to ensure that staff dose is as low as reasonably achievable and that all relevant national requirements are met.

## Adjunctive treatments

There has been some evidence to suggest that bone grafting can improve the outcome of coronectomy. A study by Elo *et al.*, followed 78 patients from five to nine years after coronectomy with bone grafting, and demonstrated marked improvement in post-operative probing depths and bone levels, with no migrations or secondary procedures. Elo postulated that bone grafting may be considered for patients with probing depths of >4 mm on the distal of adjacent molar teeth.<sup>30</sup> Similarly, Leung *et al.* (2017) discussed the possibility of guided bone regeneration in reducing the risk of root exposure after coronectomy procedures.<sup>31</sup>

## Conclusion

Coronectomy is a valid procedure as an alternative to surgical removal of wisdom teeth in high-risk wisdom cases. It is important for the general dental practitioner to clinically and radiographically assess this when referring for coronectomy, as well as gaining the confidence to deal with lower risk teeth in practice.

### Acknowledgements

A special thank you to Mr Michael Millwaters, Consultant in Oral and Maxillofacial Surgery, Princess Alexandra Hospital, for use of the radiographs of the patients at the trust.

- Patel V, Moore S, Sproat C. Coronectomy—oral surgery's answer to modern day conservative dentistry. *Br Dent J* 2010; **209**: 111–114.
- Leung Y Y, Cheung L K. Safety of coronectomy *versus* excision of wisdom teeth: a randomized controlled trial. *Oral Surg Oral Med Oral Path Oral Radiol Endodon* 2009; **108**: 821–827.
- Leung Y Y, Cheung L K. Coronectomy of the lower third molar is safe within the first 3 years. *J Oral Maxillofac Surg* 2012; **70**: 1515–1522.
- Renton T. Prevention of iatrogenic inferior alveolar nerve injuries in relation to dental procedures. *Dent Update* 2010; **37**: 350–363.
- Rood J P, Shehab B A. The radiological prediction of inferior alveolar nerve injury during third molar surgery. *Br J Oral Maxillofac Surg* 1990; **28**: 20–25.
- Renton T, Hankins M, Sproate C, McGurk M. A randomised controlled clinical trial to compare the incidence of injury to the inferior alveolar nerve as a result of coronectomy and removal of mandibular third molars. *Br J Oral Maxillofac Surg* 2005; **43**: 7–12.
- Pogrel M A, Lee J S, Muff D F. Coronectomy: a technique to protect the inferior alveolar nerve. *J Oral Maxillofac Surg* 2004; **62**: 1447–1452.
- Knutsson, K, Lysell, L, Rohlin M. Postoperative status after partial removal of the mandibular third molar. *Swed Dent J* 1989; **13**: 15.
- O'Riordan B C. Coronectomy (intentional partial odontectomy of lower third molars). *Oral Surg Oral Med Oral Pathol Oral Radiol Endod.* 2004; **98**: 274.
- Hatano Y, Kurita K, Kuroiwa Y, Yuasa H, Arijii E. Clinical evaluations of coronectomy (intentional partial odontectomy) for mandibular third molars using dental computed tomography: A case control study. *J Oral Maxillofac Surg* 2009; **67**: 1806–1814.
- McArdle L W, Renton T. The effects of NICE guidelines on the management of third molar teeth. *Br Dent J* 2012; **213**: 8.
- Loescher A R, Smith K G, Robinson P P. Nerve damage and third molar removal. *Dent Update* 2003; **30**: 375–382.
- Neugebauer, J, Shirani, R, Mischkowski R.A *et al.* Comparison of cone-beam volumetric imaging and combined plain radiographs for localization of the mandibular canal before removal of impacted lower third molars. *Oral Surg Oral Med Oral Path Oral Radiol Endodont* 2008; **105**: 633–642.
- Renton T. Update on coronectomy. A safer way to remove high risk mandibular third molars. *Dent Update* 2013; **40**: 362–368.
- Freedman G L. Intentional partial odontectomy. *J Oral Maxillofac Surg* 1997; **55**: 524–526.
- Ahmed C, Wafae el W, Bouchra T. Coronectomy of Third Molar: A Reduced Risk Technique for Inferior Alveolar Nerve Damage. *Dent Update* 2011; **38**: 267–276.
- Whaites E, Drage N. *Essentials of dental radiography and radiology.* Elsevier, 2013.
- Barracough, J, Power, A, Pattni A. Treatment planning for mandibular third molars. *Dent Update* 2017; **44**: 221–228.
- Eyrich G, Seifert B, Matthews F *et al.* Dimensional imaging for lower third molars: is there an implication for surgical removal? *J Oral Maxillofac Surg* 2011; **69**: 1867–1872.
- SEDENTEXCT. Radiation protection N° 172: Cone beam CT for dental and maxillofacial radiology. Evidence Based Guidelines. Available at [http://www.sedentext.eu/files/radiation\\_protection\\_172.pdf](http://www.sedentext.eu/files/radiation_protection_172.pdf) (accessed April 2018).
- Heurich, T, Ziegler, C, Steveling, H, Wörtche, R, Mühlring, J, Hassfeld S. Digital volume tomography extension to the diagnostic procedures available for application before surgical removal of third molars. *Mund Kiefer-und Gesichtschirurgie* 2002; **6**: 427–432.
- Nakagawa, Y, Kobayashi, K, Ishii, H, Mishima, A, Asada, K, Ishibashi K. Preoperative application of limited cone beam computerized tomography as an assessment tool before minor oral surgery. *Int J Oral Maxillofac Surg* 2002; **31**: 322–326.
- Nakagawa Y, Ishii H, Nomura Y *et al.* Third molar position: reliability of panoramic radiography. *J Oral Maxillofac Surg* 2007; **65**: 1303–1308.
- Friedland, B, Donoff, B, Dodson T B. The use of 3dimensional reconstructions to evaluate the anatomic relationship of the mandibular canal and impacted mandibular third molars. *J Oral Maxillofac Surg* 2008; **66**: 1678–1685.
- Nakayama K, Nonoyama M, Takaki, Y *et al.* Assessment of the relationship between impacted mandibular third molars and inferior alveolar nerve with dental 3dimensional computed tomography. *J Oral Maxillofac Surg* 2009; **67**: 2587–2591.
- Tantanapornkul, W, Okochi, K, Bhakdinaronk, A, Ohbayashi, N, Kurabayashi T. Correlation of darkening of impacted mandibular third molar root on digital panoramic images with cone beam computed tomography findings. *Dentomaxillofac Radiol* 2009; **38**: 11–16.
- Lübbers H T, Matthews F, Damerou G *et al.* Anatomy of impacted lower third molars evaluated by computerized tomography: is there an indication for 3dimensional imaging? *Oral Surg Oral Med Oral Path Oral Radiol Endod* 2011; **111**: 547–550.
- Suomalainen, A, Ventä, I, Mattila, M, Turtola, L, Vehmas, T, Peltola J S. Reliability of CBCT and other radiographic methods in preoperative evaluation of lower third molars. *Oral Surg Oral Med Oral Path Oral Radiol Endod* 2010; **109**: 276–284.
- Yamada T, Ishihama, K, Yasuda K *et al.* Inferior alveolar nerve canal and branches detected with dental cone beam computed tomography in lower third molar region. *J Oral Maxillofac Surg* 2011; **69**: 1278–1282.
- Elo J.A, Sun H H B, Dong F, Nguyen K, Zakhary K. Does bone grafting improve outcomes in coronectomy surgery? Long-term (5to 9year) clinical and radiographic follow-up of 78 adult patients. *J Oral Maxillofac Surg* 2017; **75**: 1330–1337.
- Leung YY. Coronectomy of lower third molars with and without guided bony regeneration: a pilot study. *Br J Oral Maxillofac Surg* 2016; **54**: 155–159.