

CORONECTOMY: AN ALTERNATIVE THERAPY FOR THE SYMPTOMATIC, IMPACTED THIRD MOLAR

REPORT OF 9 CASES

NIKA VAFAEI¹, CARLO FERRETTI²

Key words: impacted third molar, coronectomy

The mandibular third molar remains the tooth most prone to impaction and interestingly, the incidence of impaction appears to be increasing.¹ Mechanisms for impaction of third molars remain unproven supposition,² but the result is the failure of eruption into a normal functional position.² Problems which may arise due to tooth impaction (be it partial or full) include pericoronitis, cheek biting, pressure on adjacent teeth causing pain, food impaction in the area, buccal or lingual eruption, pericoronal infection, caries, periodontal problems with associated teeth, and association with pathological lesions such as cysts and tumours.² Thus, the obligatory surgical removal of wisdom teeth remains a common procedure in dental practice. Prophylactic removal to avoid the aforementioned problems is often performed but it is a persistent source of discussion. Adding to the controversy is the proposed association between third molar impaction, anterior incisor crowding and atypical facial pain.^{2,3}

Irrespective of the motive, the surgical removal of wisdom teeth may be associated with several post-operative complications. The most commonly observed complications include pain, edema, acute alveolar osteitis, infection, mandibular fracture, damage to adjacent teeth, and haemorrhage.^{1,4-7} Possibly the most concerning complication is temporary or permanent sensory nerve damage.^{1,2,4,6,8}

The development of a post-operative complication is influenced by operator, patient, and tooth associated factors. There is a strong correlation between the degree of impaction, the type of impaction (i.e. vertical, mesioangular, distoangular

and horizontal), and the anatomical relation of the roots to the inferior alveolar nerve canal and postoperative complications. A preexisting infection or a pathological lesion in or around the tooth also increases the risk.^{7,9} An important iatrogenic factor is surgeon experience. Several studies have confirmed the inverse relationship between surgeon experience and complications.⁹⁻¹³ Surgical technique as well as the use of certain instrumentation are potential risk factors, in particular with regard to nerve damage.⁹⁻¹³

Lingual nerve (LN) and inferior alveolar nerve damage (IAN) is largely attributed to the anatomical proximity of the impacted third molar to these nerves. Both the IAN and the LN arise from the posterior branch of the mandibular nerve which in turn is a branch of cranial nerve V, the trigeminal nerve. The IAN consists predominantly of sensory fibres with only a few motor fibres (distributed via the mylohyoid nerve to the mylohyoid muscle and the anterior belly of the digastric muscle). The lower molar and premolar teeth and adjacent parts of the gingiva are supplied by the IAN, and its terminal branches supply sensation to the ipsilateral lower lip via the mental nerve. The course of the IAN within the mandibular canal proceeds anteriorly from the medial aspect of the mid-ramus (at the lingula) along with the inferior alveolar artery (together they are referred to as the inferior alveolar neurovascular bundle) in the intraosseous inferior alveolar canal. It is here that its course approximates the third molar to varying degrees. The nerve proceeds anteriorly in its bony canal within the body of the mandible just apical to the lower molars and premolars to emerge from the mental foramen as the terminal mental nerve branch which innervates the skin of the ipsilateral chin and the lower lip. The smaller incisive branch is the intraosseous anterior continuation of the nerve and supplies the canine and incisor teeth.¹⁴ The lingual nerve runs its course anterior to the inferior alveolar nerve, proceeding anteriorly in the soft tissues lingual to the third molar and supplies the mucous membrane of the anterior two-thirds of the tongue.¹⁴

Important predictors of neural injury include the use of lingual retractors, particular surgical techniques such as vertical

1. Niko Vafaei, BDS,
Public Service, Community Service, Kwa-Zulu Natal, South Africa

2. Carlo Ferretti, BDS, MDent, FCD(SA), MFOS
Private Practice – Bedford Gardens Clinic, Bedfordview, Johannesburg, South Africa
Senior Specialist – Division of Maxillofacial and Oral Surgery, Chris Hani Baragwanath Hospital and University of the Witwatersrand, Johannesburg, South Africa

Corresponding author:

Dr Carlo Ferretti

P.O Box 75471, Gardenview, 2047, South Africa • Tel: 0027 11 615 9595

Facsimile: 0027 11 616 8649 • E-mail: ferretti@mweb.co.za

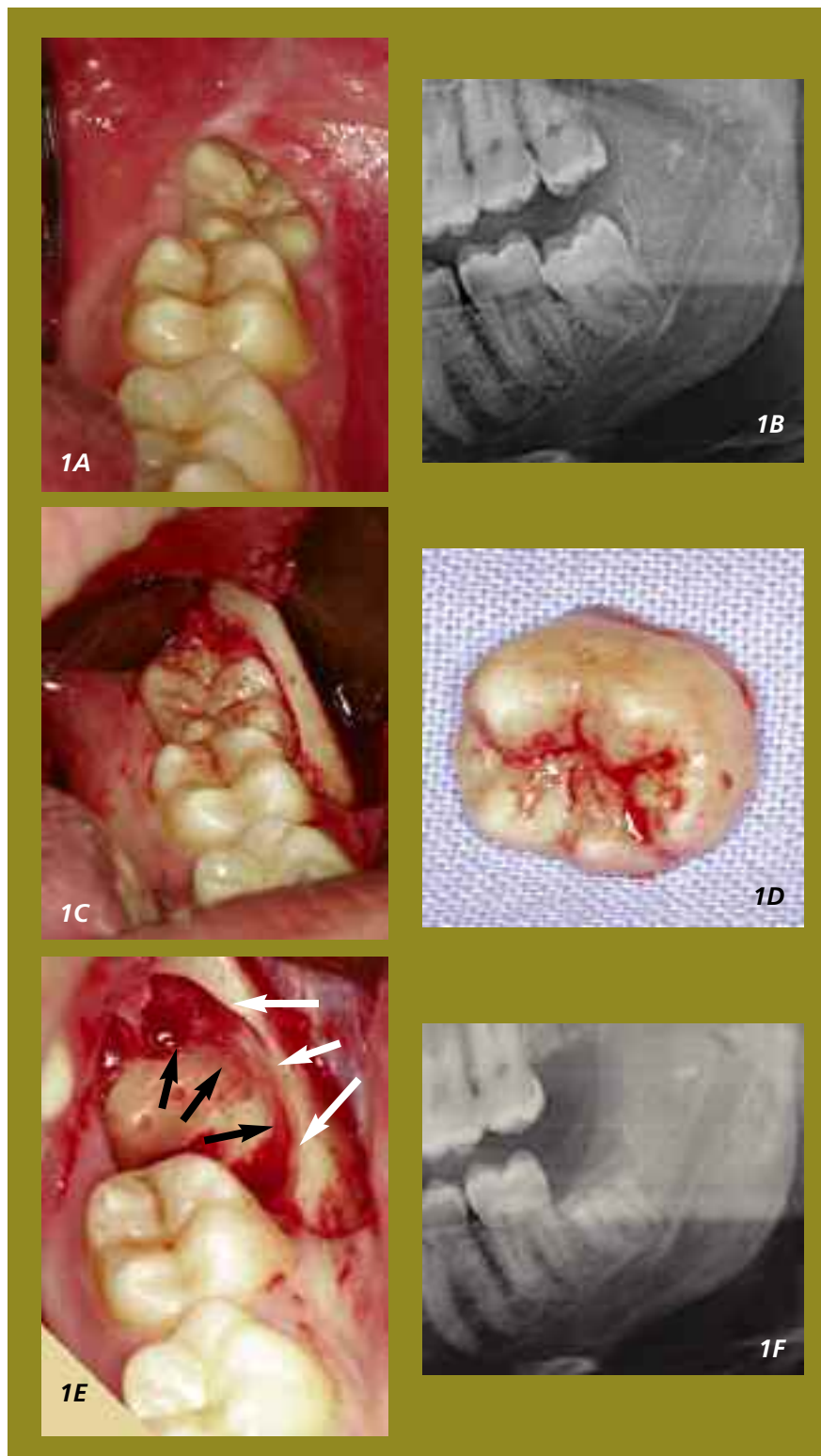


Figure 1 – 32 year old male patient with partially erupted, vertically impacted 38 (A) which on panoramic radiographs demonstrates an intimate relationship of the root apices to the inferior alveolar canal (B). The crown is exposed by means of a mucoperiosteal flap (C) and the crown resected (D). The retained roots (black arrows indicating the tooth margin) are reduced to a sub-crestal level (white arrows indicate the osseous socket margin). This leaves undisturbed, retained root fragments below the socket margin allowing for bone formation above the roots.

tooth sectioning and ostectomy, anatomical variations of nerve, and lingual root angulation. The mechanism of nerve injury (compression, stretching or complete transection) is a strong determinant of sensory alteration and recovery¹⁵, as is

increased patient age. The latter is due to the increased difficulty of surgery and the decreased potential for repair and regeneration in older patients.^{15,16} The reported incidence of LN and IAN damage following third molar extraction ranges

between 0 and 23 %.¹¹ More recent data has however reported the incidence to be in a lower range of 0-3.6%.^{10-13, 16, 17} Whether temporary or permanent, iatrogenic nerve damage following extraction of the lower third molar is a common cause of litigation and patient dissatisfaction in dental practice.¹⁰ This complication can be mitigated to some degree by preoperative risk assessment. The three most common radiographic features suggesting close proximity of an impacted third molar to the IAN include diversion of the canal, interruption of the canal walls, and darkening of the root.^{12, 18, 19} The advent of cone beam computed tomography has significantly increased the accuracy of preoperative assessment but its expense precludes it from widespread availability and routine use.

The decision to remove impacted third molars is the culmination of a complex algorithm which must evaluate the reasons for removal and weigh these against the potential risk factors. The fundamental tenet of surgical exodontia is that the prophylactic removal of any tooth which has a high risk for complications (whether due to local conditions or systemic factors) cannot be condoned. Once a decision has been made that the benefits of surgical removal of a tooth outweigh any potential complications it is incumbent upon the practitioner to select a surgical technique with the lowest potential complication rate. Ecuyer and Debien²⁰ first described a technique, which they termed coronectomy, involving the resection of the crown of a tooth with deliberate retention of the roots.^{18,19} This technique may be considered when an impacted lower third molar must be removed and key radiographic findings show close relation of the tooth roots with the inferior alveolar nerve canal, in order to mitigate the risk of IAN damage during tooth extraction.^{18,19} The procedure requires transection of the tooth just below its crown and reduction of the remaining root fragments below the lingual and buccal plates (Fig. 1), allowing for bone formation superior to these roots.²¹ Following retention of vital roots all pulps survive¹⁸, however root mobility must be avoided during the coronectomy procedure as these will become a source of infection.^{18,21} Exclusion criteria for coronectomy include a tooth with active infection extending to its roots, periapical pathology associated with the tooth, and mobile teeth. Postoperatively, although retained root movement is unpredictable, they appear to migrate away from the canal (Fig. 2) allowing removal at a later stage (if required) with substantially lower risk of nerve damage.²¹ Complications associated with coronectomy include osteitis, unintentional root mobility with subsequent infection, and temporary sensory disturbance of the lip related to the technique and

damage caused by inappropriate burr usage.¹⁸

Recently this technique has been subject to closer scrutiny and several studies have been published on the topic. In a study by Pogrel et al²¹, forty-one patients had 50 lower third molars treated by coronectomy. There were no cases of inferior alveolar nerve damage; there was however one case of transient lingual nerve involvement, probably due to lingual retractor use. One patient required subsequent removal of the roots of both lower third molars because of failure to heal, and one patient required subsequent removal of a root because of subsequent migration to the surface. Root migration was noted in approximately 30% of patients over a 6 month period.²¹ O’Riordan¹⁸ conducted a retrospective study of 52 patients who were operated over a 10 year period. 3 of 52 patients had to have the roots removed subsequent to the coronectomy procedure due to pain or infection. Neural complications included 3 cases of temporary sensory disturbance of the lower lip which the author attributes to pressure transmitted to the nerve when splitting the crown from the root, or a slight elevation of the root when splitting. One case of prolonged anesthesia of the lip was noted, due to bur damage.¹⁸ Finally, a prospective randomized study by Renton et al¹⁹ of 128 patients requiring operations on mandibular third molars which had radiographic evidence of proximity to the inferior alveolar canal nerve. Patients were randomly assigned to either the extraction [n = 102] or the coronectomy [n = 94] group. Some roots were dislodged during intended coronectomy and were therefore removed, resulting in two subgroups (successful coronectomy n = 58, and failed coronectomy n = 36). Nineteen nerves were damaged (19%) after extraction, none after successful coronectomy, and three (8%) after failed coronectomy (p = 0.01). The incidence of dry socket infection was similar in the three groups (10/102, 10%, 7/58, 12%, and 4/36, 11%, respectively). The incidence of acute localized osteitis was found in 10–12% in all groups. Follow up of the coronectomy procedure after 13 months showed five root segments had started to migrate.¹⁹

Case reports

To the above mentioned cases we add our own experience with a further 9 patients. All patients were offered coronectomy if clinical examination revealed an impacted third molar which has been repeatedly symptomatic and radiographic examination suggested a high risk of inferior alveolar injury. All patients (4 male and 5 female with ages ranging from 19 to 36 years of age) were given a detailed account of all the treatment options and the principles of

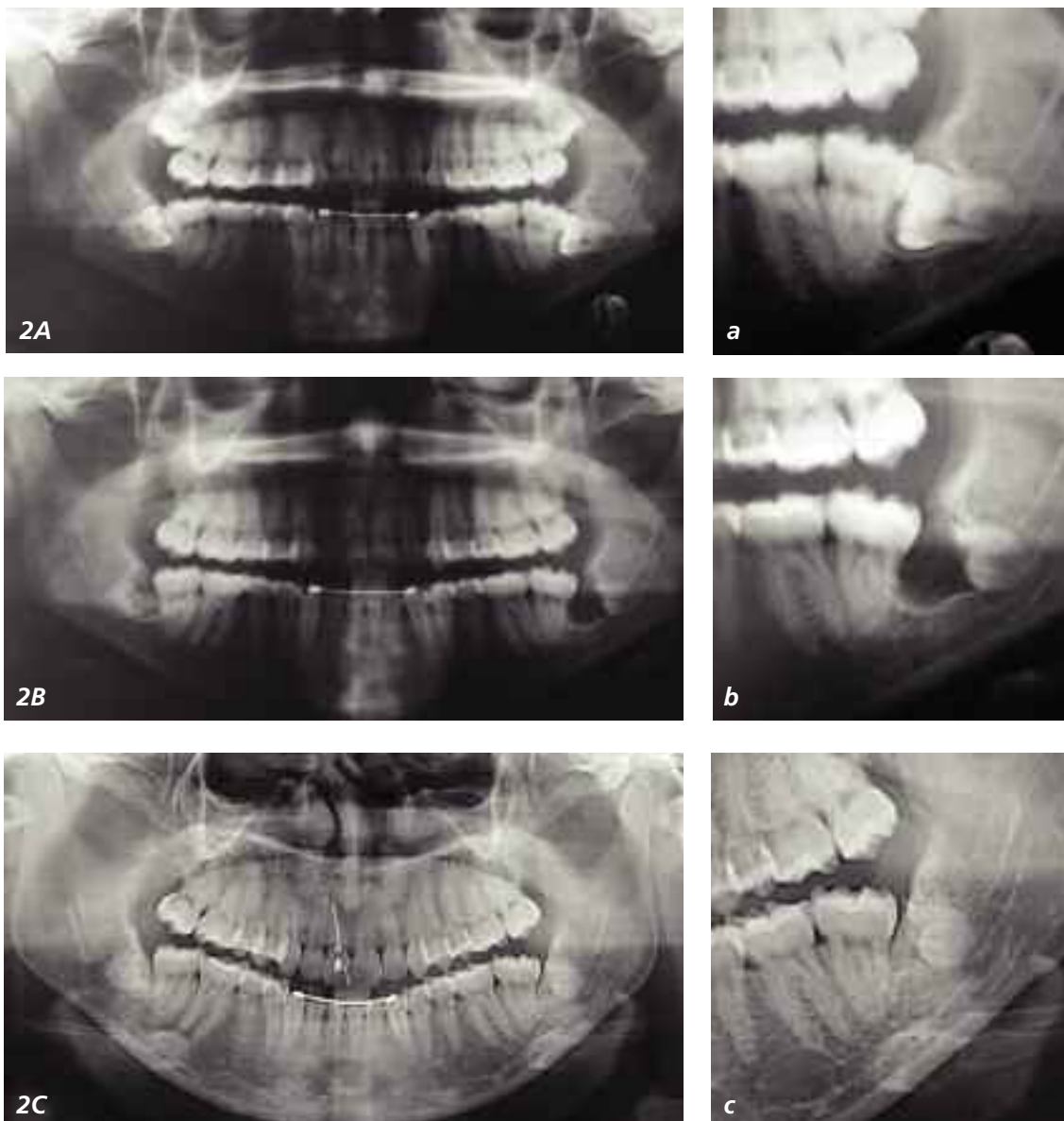


Figure 2 – Panoramic radiograph of 22 year old female patient presenting with persistent pain associated with horizontally impacted teeth (A, a). Due to high risk of IAN injury (note darkening of canal as it crosses the roots) bilateral coronectomy was performed (B, b). 1 year follow-up (C, c) shows significant root fragment migration away from the IAN, ossification anterior to the roots and absence of periapical pathology

coronectomy, and were operated by the same surgeon. 3 of these patients had both lower wisdom teeth treated by coronectomy; the remaining 6 patients had a single wisdom tooth treated by coronectomy. This resulted in 12 teeth planned for coronectomy, of which one tooth required complete removal due to inadvertent dislodgement of the roots during surgery. Post operative follow-up period ranged from 3 months to 1 year. None of the patients developed post surgical lingual and labial anaesthesia and thus far none have

developed infection requiring subsequent root removal. Long term radiographic follow-up demonstrated considerable root migration away from the inferior alveolar canal (Fig. 2)

Discussion

Justifiably, the new technique of coronectomy is advocated with caution and some surgeons have expressed resistance to the adoption of this treatment alternative as it is contrary to the dogma of exodontia. Given its recent emergence, a

significant limitation is the lack of long term follow up, in particular with regard to the potential risk of an intentionally retained root. It is proposed that the roots may become a source of infection, leading to an apical periodontitis following pulp necrosis, which could spread to the inferior alveolar canal given the root proximity.²² Questionable outcomes also include the variable rate of root migration, periodontal status in the region, and the need for repeated radiographic and clinical evaluation, and a possible second operation to remove symptomatic roots.²³ Though not justifying the routine use of this procedure, Garcia-Garcia mentions that following breakage of the apex during conventional wisdom tooth extraction in close proximity to the IAN, the roots should probably not be removed.²⁴ It must be said that these contrarian views are anecdotal and no well structured study we are aware of has supported these views. On the contrary, the aforementioned studies and our experience corroborate that coronectomy is a treatment alternative with a very low complication rate. Should root removal subsequently become necessary, the root migration that follows coronectomy may decrease the risk of neural injury as the retained roots are no longer intimately associated with inferior alveolar neurovascular bundle.

Given the unpredictability of lower third molar removal, it is not always possible to avoid potential injury. However, awareness of the various associated risk factors makes it possible to minimize consequences, if not prevent them all together.

IAN involvement during lower third molar extraction is a cause for concern as it is both a clinical and medico legal issue.²¹ The coronectomy technique diminishes the possibility of nerve injury thus avoiding patient dissatisfaction, and also offers a less traumatic approach than conventional third molar removal. Whilst widespread acceptance of coronectomy rightly awaits the results of longer term follow-up studies, the preliminary results are encouraging, and the practitioner who routinely removes impacted wisdom teeth should consider this surgical option in selected patients.

References

1. Chaparro-Avendaño AV. Morbidity of third molar extraction in patients between 12 and 18 years of age. 2005; 10(5):422-3.
2. Hamasha AA. Reasons for Third Molar Teeth Extraction in Jordanian Adults. J Contemp Dent Pract 2006; (7)5:088-095.
3. Al-Balkhi KM . The Effect of Different Lower Third Molar Conditions on the Re-Crowding of Lower Anterior Teeth in the Absence of Tight Interproximal Contacts One-Year Post Orthodontic Treatment: A Pilot Study. J Contemp Dent Pract 2004; 3:066-073.
4. Huang IY, Wu CW. The displaced lower third molar: a literature review and suggestions for management. J Oral Maxillofac Surg 2007;

65 (6): 1186-90.

5. Lacasa JM, Jimenez JA. Prophylaxis versus pre-emptive treatment for infective and inflammatory complications of surgical third molar removal: a randomized, double blind, placebo controlled, clinical trial with sustained release amoxicillin/clauvanic acid. Int J Oral Maxillofac Surg 2007; 36(4): 321-7.

6. Wagner KW, Schoen R. Complicated late mandibular fracture following third molar removal. Quintessence Int 2007; 38(1): 63-5.

7. Woldenburg Y, Gatot I. Iatrogenic mandibular fracture associated with third molar removal: Can it be prevented? Medical Oral Patol Oral Cir Bucal. 2007; 12(1): e70-2.

8. Song F, O'Meara S. The effectiveness and cost-effectiveness of prophylactic removal of wisdom teeth. Health Technology Assessment 2000; 4(15): 1-55.

9. Blondeau F, Daniel N. Extraction of impacted mandibular third molars: postoperative complications and their risk factors. Journal of Canada Dental Association 2007; 73(4):325.

10. Valmaseda-Castellon E, Berini-Aytes L. Lingual nerve damage after third lower molar surgical extraction. Oral Surg Oral Med Oral Path Oral Radiol Endod 2000; 90(5): 567-73.

11. Bataineh A. Sensory nerve impairment following mandibular third molar surgery. J Oral Maxillofac Surg 2001; 59:1012-1017.

12. Ban Guan Tay A, Ser Go W. Effect of exposed inferior alveolar neurovascular bundle during surgical removal of impacted lower third molars. J Oral Maxillofac Surg 2004; 62: 592-600.

13. Rehman K, Webster K. Links between anaesthetic modality and nerve damage during lower third molar surgery. British Dental Journal 2002; 192(1): 43-45.

14. Moore, K. L. Clinically Oriented Anatomy. 3rd Ed. Philadelphia Lippincott Williams & Wilkins, 1992. Pgs 663-668, 863-868.

15. Jerjes W, Moles DR. Permanent sensory nerve impairment following third molar surgery: a prospective study. Oral Surg Oral Med Oral Pathol Oral Radiol Endod 2006; 102: e1-e7.

16. Queral-Godoy E, Berini-Aytes L. Incidence and evolution of inferior alveolar nerve lesions following lower third molar extraction. Oral Surg Oral Med Oral Path Oral Radiol Endod 2005; 99(3): 259-64.

17. Valmaseda-Castellon E, Berini-Aytes L. Lingual nerve damage after third lower molar surgical extraction. Oral Surg Oral Med Oral Path Oral Radiol Endod 2001; 92: 377-83.

18. O'Riordan BC. Coronectomy (intentional partial odontectomy of lower third molars). Oral Surg Oral Med Oral Path Oral Radiol Endod 2004; 98(3): 274-80.

19. Renton T, Hankins M. A randomized controlled clinical trial to compare the incidence of injury to the inferior alveolar nerve as a result of coronectomy and removal of mandibular third molars. Br J Oral Maxillofac Surg 2005; 43: 7-12.

20. J. Ecuyer and J. Debien. Deductions operatoires. Actualités Odonto-Stomatologiques 1984 ; 148 : 695-701.

21. Pogrel MA. Coronectomy: A technique to protect the inferior alveolar nerve. J Oral Maxillofac Surg 2004; 62: 1447-1452.

22. Garcia-Garcia, A. Coronectomy: a questionable procedure. J Oral Maxillofac Surg 63:723-725, 2005.

23. Assael, LA. "Coronectomy: A time to ponder or a time to act?" J Oral Maxillofac Surg 2004; 62(12): 1445-1446.

24. Garci-Garcia, A. "Is coronectomy really preferable to extraction?" Br J Oral Maxillofac Surg. 2006; 44(1): 75.