



Tara Renton

Update on Coronectomy. A Safer Way to Remove High Risk Mandibular Third Molars

Abstract: Decoronation of high risk mandibular third molars (M3Ms) has become common practice in parts of UK and USA. With the introduction of Cone Beam CT scanning, there has been an evolution in the practice, with avoidance of unnecessary coronectomies based on CBCT findings. Also, additional anatomical features found only on CBCTs have introduced possible additional indications to undertake intentional coronectomy.

Trigeminal nerve injury is the most problematic consequence of dental surgical procedures with major medico-legal implications. Iatrogenic injuries to the third division of the trigeminal nerve remain a common and complex clinical problem. Altered sensation and pain in the orofacial region may interfere with speaking, eating, kissing, shaving, applying make-up, toothbrushing and drinking; namely just about every social interaction we take for granted. Usually after oral rehabilitation, the patient expects and experiences significant improvements, not only regarding jaw function, but also in relation to dental, facial, and even overall body image. Thus these injuries have a significant negative effect on the patient's self-image and quality of life and the iatrogenesis of these injuries lead to significant psychological effects.

Clinical Relevance: Coronectomy is an alternative procedure to complete removal of a mandibular third molar in situations where there is high risk of damage to the inferior alveolar nerve.

Dent Update 2013; 40: 362–368

Third molar surgery-related inferior alveolar nerve injury is reported to occur in up to 3.6% of cases permanently and 8% of cases temporarily.^{1,2} Factors associated with Inferior Alveolar Nerve Injury (IANI) are age, difficulty of surgery and proximity to the IAN canal. If the tooth is closely associated with the IAN canal radiographically, 20% of patients having these teeth removed are at risk of developing temporary IAN injury and 1–4% are at risk of permanent injury.^{1–5}

Radiographic signs indicative of possible IAN risk include:

- Diversion of the canal;
- Darkening of the root (Figure 1a);

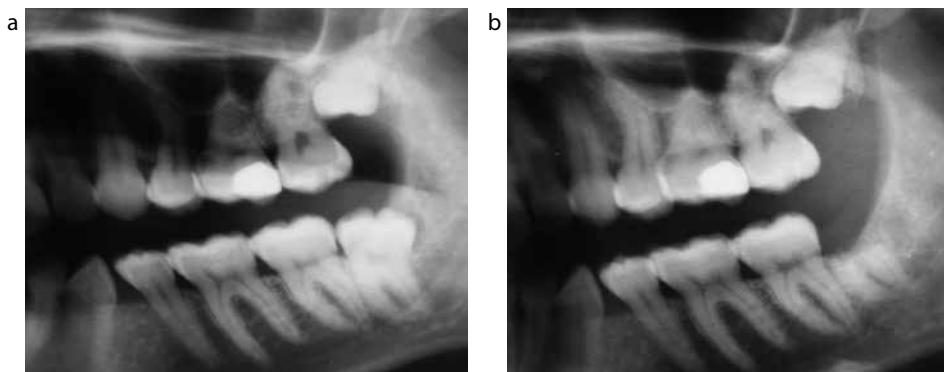


Figure 1. Sectional dental pantomogram of LL8, (a) pre- and (b) post-coronectomy.

- Interruption of the canal lamina dura;
- Juxta-apical area.

If these plain film radiographic risk factors are identified, removal of the third molar will result in elevated risk of IANI (2% permanent and 20% temporary). The patient must be informed about this elevated risk prior to extraction.

Coronectomy reduces the likelihood of nerve injury by ensuring retention of the vital roots when they are close to the inferior alveolar canal (as estimated on radiographs or CBCT) (Figure 1). The method aims to remove only the crown (all enamel) of an impacted mandibular third molar while leaving the root and pulp undisturbed, thereby

Tara Renton, BDS, MDS, PhD, FDS RCS, FRACDS (OMS) FHEA, Oral Surgery, King's College London Dental Institute, King's College Hospital Foundation Trust, Denmark Hill Campus, Bessemer Road, London SE5 9RS, UK.

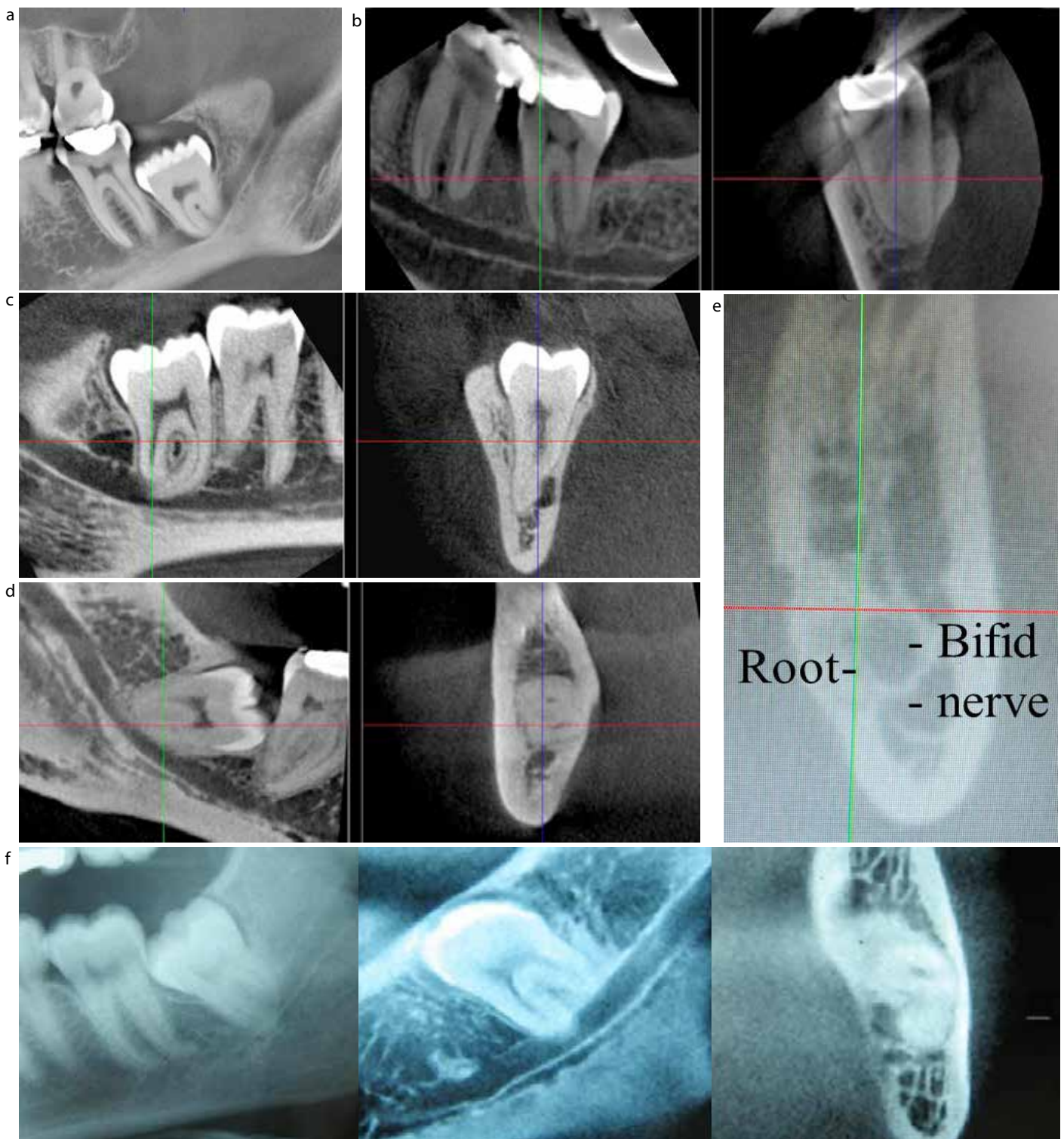


Figure 2. (a) DPT of mandibular third molar crossing at least 50% of the canal with additional radiographic signs (loss of LD, darkening of roots and deviation of canal) indicates high risk and assessment by CBCT is recommended. (b) CBCT of mandibular third molar roots identified as high risk on DPT but they appear to be distant, inferior and buccal to IDC allowing for removal. (c) CBCT of mandibular third molar roots identified as high risk on DPT and they appear to be proximal to IDC with loss of cortication which may indicate coronectomy. (d) CBCT of mandibular third molar roots identified as high risk on DPT and they appear to be proximal to IDC but maintaining cortication may indicate possible removal. (e) CBCT of mandibular third molar roots identified as high risk on DPT illustrating bifid canals reported in over 30% of cases. (f) DPT and CBCT of mandibular third molar roots identified as high risk on DPT and the IDC appears to be inter-radicular with loss of cortication and 'snaking' through tooth roots: ABSOLUTE indication for coronectomy.

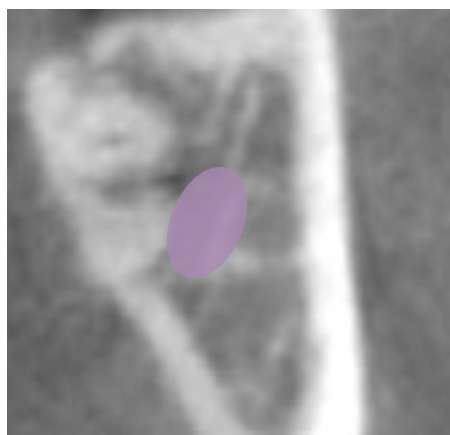


Figure 3. An ICat CBCT image of an M3M root proximal and lingual to the IDC (purple) with the lack of lingual plate.

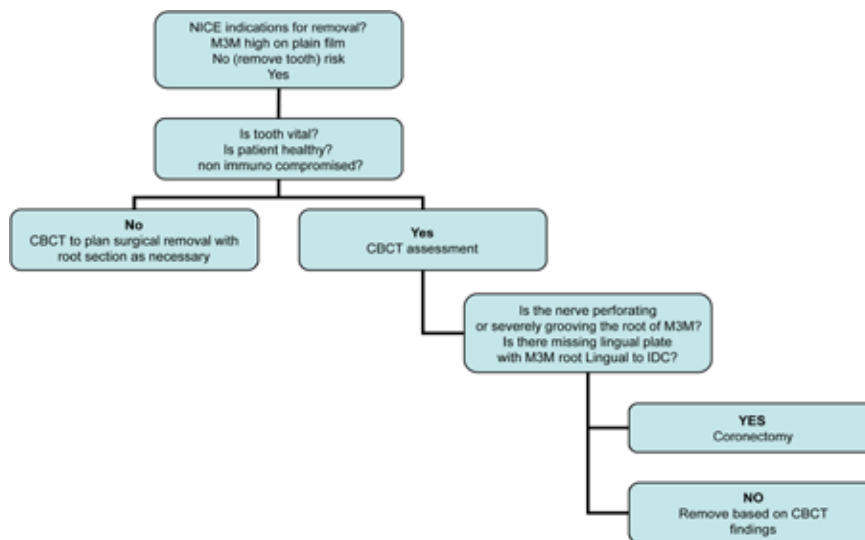


Figure 4. Algorithm for coronectomy decision.

avoiding direct or indirect damage to the IAN.

More recently it has become common practice in many centres to undertake cone beam CT (CBCT) scanning of mandibular third molars (M3Ms) that are considered proximal to the Inferior Dental Canal (IDC) and may be at high risk of causing inferior alveolar nerve injury (IANI)(Figure 2a). In 2007 Tantanapornkul *et al*⁶ assessed 161 teeth and reported the relative sensitivity of CBCT and panoramic assessment to be 93% and 70% and the specificity CBCT and panoramic assessment to be 77% and 63%. Sensitivity measures the proportion of actual positives which are correctly identified as such (eg the correct diagnosis). Specificity measures the proportion of negatives which are correctly identified (eg correctly identified as disease free).

In 2009 Jhamb *et al*⁷ compared spiral CT with panoramic assessment and found no significant differences in 31 teeth. Most third molar roots in close proximity to the IAN canal were buccal (45%), 39% were in line with the canal, 10% were lingual and 6.4% were inter-radicular. The percentage of roots more than 6mm from the nerve was 20%, 0–1mm (3%), 0mm with cortication (48%), and 0mm with cortical break (29%). Friedland *et al*⁸ highlighted the benefits of CBCT imaging for the assessment of high risk third molars.

In a more recent study, Umar *et al*⁹ reported that, in 50 high risk M3Ms, the 78% with darkening roots on the panoral correlated with loss of cortication on CBCT in 68% of cases: 66% of cases displayed thinning or loss of the lingual cortical plate, 33% of which were related to the IDC and 30% the tooth itself.

Overall, there was a loss of cortication of the tooth in 33% of cases, an indication that the roots were in close proximity to the IDC.

Therefore, there is increasing evidence that CBCT⁹ scanning of high risk teeth will further establish the relationship between the IAN and the roots (Figure 2b). In many cases, the CBCT reaffirms the proximal relationship which would support planned coronectomy, if appropriate (Figure 2c). However, in a few incidences, despite high risk identification based on plain films, some IANs are found to be distant from the roots using CBCT (approximately 30–50%),^{7–9} which would allow for removal of the tooth rather than planned coronectomy (Figure 2d).¹⁰ Further research is required to ascertain the risk benefits of CBCT and whether it is indicated for treatment planning in these high risk cases.

There are increasing numbers of reports of bifurcation of the IDC proximal to the M3M region (Figure 2e). This will have specific significance when ensuring, on reporting of the relationship, that subsidiary branches perforating the M3M are not overlooked (Figure 2f).

Based on the author's experience, CBCT has proven to have an explicit role in the pre-operative assessment for removal of high risk M3Ms in a unit that regularly undertakes coronectomy procedures. In 33% of cases, the tooth is proximal to the IAN canal and the lingual plate (Figure 3) may be absent.⁹

A recent report¹¹ also highlights the likelihood of branching of the IDC in relation

to the M3M, with 94.6% of canals displaying branching with most proximal to the M3M roots.

The author would only consider undertaking an intentional coronectomy (near full section of the crown from the roots) when the inferior dental canal is intricately involved with the third molar roots, or if the roots are proximal and lingual to the IDC in association with a missing lingual plate. If the IDC is merely proximal to the tooth roots, the author would plan the surgery based on the CBCT findings, with the intention of removing the roots, allowing root retention only when the roots are completely immobile on initial elevation after bone removal. In those cases where the root is distant to the IDC, or the patient is compromised, or the tooth non vital, then the tooth should be removed, and CBCT may play a role in assisting the surgeon to plan the tooth section in order to minimize damage to the IAN during necessary tooth removal (Figure 4).

Although coronectomy was first described in 1989,¹² only six of nine published studies^{5,12–16} explicitly use coronectomy, and the technique is yet to gain popularity because of surgeons' concerns about the outcomes and short- and long-term complications. However, outcomes related to treatment of neurosensory disturbance after wisdom tooth surgery remain variable; so coronectomy – if proven to be safe – could be useful in minimizing the occurrence of neurosensory deficit of M3Ms that are at high risk of nerve damage.

The six most recent articles on

coronectomy consist of two randomized controlled trials, two prospective cohort studies, one case control study and one retrospective study. Three of the six articles investigate the fate of third molars deemed high risk on a DPT radiograph that have been coronected.^{12,13,16} The remaining three articles compare the techniques of coronectomy versus complete removal of the high risk third molar tooth.^{5,14,15} Interestingly, Dolanmaz *et al*⁶ did not have a high risk control group for comparison as they deemed this unethical. All six articles suggested that the technique of coronectomy had merit and many practitioners regularly use the coronectomy approach in order to minimize IANIs.

Only two of the six articles were prospective randomized controlled trials and thus level 1 evidence.^{5,15} The number of patients involved in these studies ranged from 41¹³ to 231.¹⁵

Pogrel *et al*¹³ and Dolanmaz *et al*⁶ both stated that they completely transected the crown of the third molar from the roots so as not to mobilize roots. Pogrel *et al*¹³ raised a lingual flap and protected the lingual nerve with a retractor to avoid injury and reported one case of transient lingual nerve injury as a result of this. Dolanmaz *et al*⁶ did not state whether a lingual flap was raised. All other authors, with the exception of Hatano *et al*,¹⁴ partially sectioned the crown with a fissure bur and elevated the crown using an elevator. Others made no specific reference to the technique.

Pogrel *et al*¹³ and Dolanmaz *et al*⁶ did not state in their papers the grade of surgeon carrying out the coronectomy procedures. Renton *et al*,⁵ O'Riordan¹² and Hatano *et al*¹⁴ all stated that qualified oral surgeons carried out all surgery and Leung and Cheung¹⁵ stated that surgical residents carried out patient treatment.

Pogrel *et al*¹³ and O'Riordan¹² did not mention the medically compromised patient in the exclusion criteria. However, there does not seem to be an increased rate of coronectomy failure in their studies. Only one out of 50 cases in the Pogrel study failed to heal and required subsequent removal and, in the O'Riordan¹² study, one out of 53 patients failed to heal immediately. All papers had lower third molar teeth that appeared high risk on DPT (or CBCT, Hatano *et al*¹⁴) as their inclusion criteria.

Two out of the six studies used antibiotics. Pogrel *et al*¹³ administered pre-operative prophylactic antibiotics to all patients

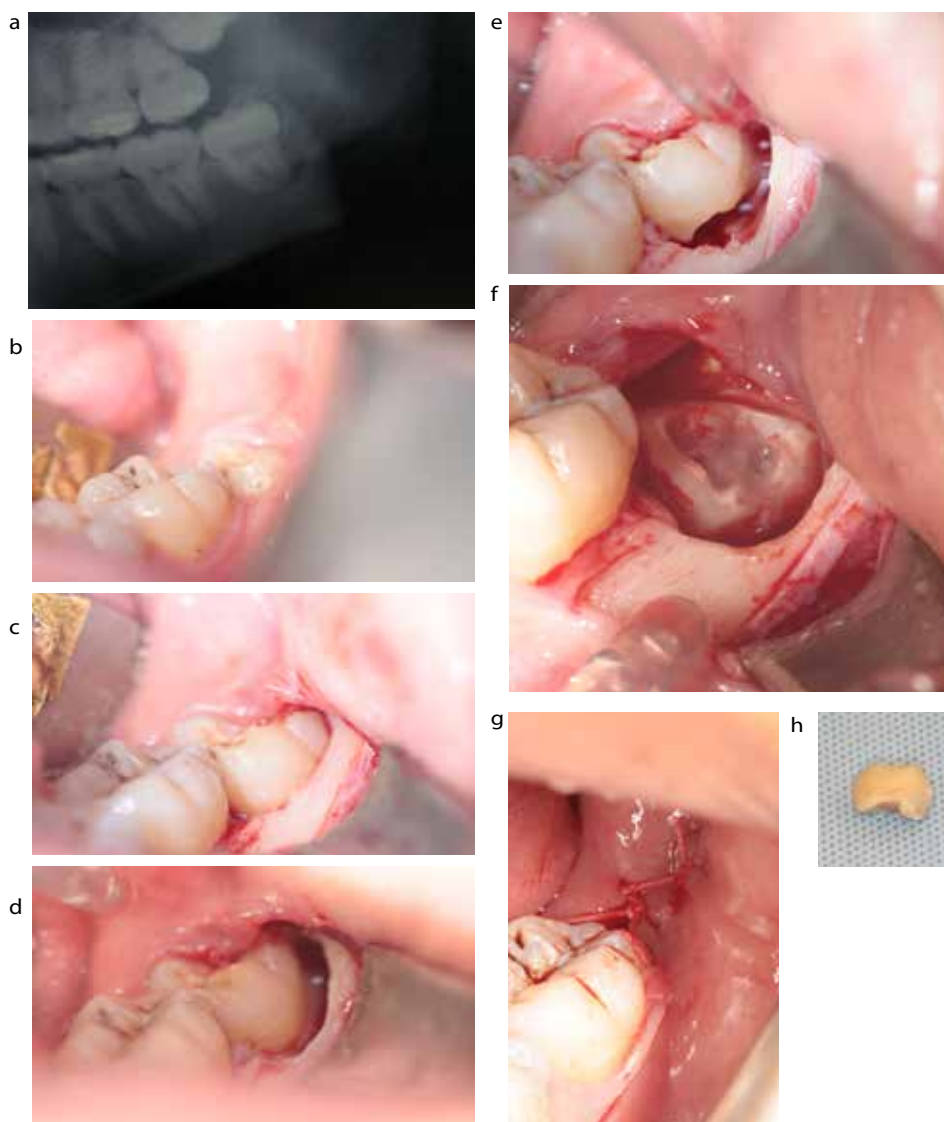


Figure 5. (a–h) The operative coronectomy technique (courtesy of Dr G Umar).

and Dolanmaz *et al*⁶ administered post-operative antibiotics to all patients. Dolanmaz *et al*⁶ reported that none of their 43 patients required a second procedure to remove retained roots and Pogrel *et al*¹³ reported one out of 41 patients requiring immediate root removal. All six papers reported their outcome as a success with low incidence of post-operative complications.

Although complications after coronectomy are rare, they include the following:

- Pain;
- Infection: alveolar osteitis;
- IANI;
- Failed coronectomy;

- Root migration; and
- Re-operation.

Tables 1 and 2 assess these complications for each study.

In essence, the consensus is that coronectomy is a useful technique to minimize inferior alveolar nerve injury in healthy patients with high risk third molars that require removal based on indications for surgery. The clinician involved should only consider undertaking this technique when they have had appropriate training and are able to follow-up the patient's treatment. This implies that they need to be in an established specialist practice with the ability to follow-up and track patients and, of course, ensure that the patient is willing to

keep in touch should complications, that they have been made aware of, arise.

The coronectomy technique

Preoperative assessment

The patient

Coronectomy is an alternative procedure to complete extraction when a tooth is deemed 'high risk' (crossing both lamina dura of the ID canal on a plain film) but vital, and in a patient who is not medically compromised (not immune compromised [diabetic, long term steroids, chemotherapy, HIV] or with the potential for poor healing [previous irradiation]). Patients should be fully cogniscent of the potential risks of a 'dry socket' (incidence 5%) and the additional possibility of a second surgical procedure either early or late post-operatively (approximately 1–2%).

Radiography

The mandibular third molar is identified as high risk based on routine plain film radiography. Once identified as high risk, a CBCT may be useful in confirming the relationship of the tooth to the inferior alveolar canal (Figure 2). If CBCT confirms that the mandibular third molar roots are inextricably involved with the IAN canal, the surgeon may elect to ensure that mobilization of the roots is prevented by an extended section of the crown from the roots, but this technique may be associated with increased risk to the lingual nerve.

Consent

The patient therefore must be consented with the words 'it is intended for a coronectomy to be undertaken, however, if the roots are mobilized during surgery they will require removal, with the heightened risk of nerve injury'.¹⁰ The patient must also be aware that there is a risk of early and late infection that will necessitate the removal of the roots which, in most cases, occurs once the tooth root has erupted away from the IAN canal but, in some cases, the root is perforated by the nerve, dragging the nerve superiorly as it erupts.¹⁴

The operative technique (Figure 5)

■ Long buccal infiltration and anterior buccal infiltration (4 ml articaine 4%) is given as with routine lower third molar surgery. An inferior

dental block (lidocaine 2%) may be used in addition, if necessary.

- A buccal triangular mucoperiosteal full thickness flap is raised to expose the third molar tooth (no lingual access).
- A fissure bur is used to remove buccal bone and expose the tooth. Creation of a narrow buccal gutter of bone adjacent to the buccal aspect of the tooth (not distal) down to the amelo-cemental junction (ACJ). This would be similar access as that gained for application points for third molar elevation but in this scenario we are trying to gain access to cut through the ACJ into the pulp.
- When the tooth roots are intricately involved with the IDC based on the CBCT the crown is sectioned from the roots for an intentional coronectomy.
- If the IDC is just proximal and the surgeon aims to remove the tooth then, before decoronating the tooth, an elevator (Luxator or Warwick James) is used to 'mobilize' the tooth where possible. If mobilization occurs easily, the tooth should be sectioned and removed with root division as required (based on findings from previous CBCT scanning). If the tooth is 'stuck' then coronectomy should be undertaken.
- A fissure bur is then used and drilled directly into the pulp at the mid centre of the buccal groove intersection with the ACJ. This cut is lateralized to create a narrow horizontal groove in the tooth just below the ACJ. The depth of this cut needs to be into the pulp then lateralized, but no more than the length of the fissure bur, so as to avoid perforation of the lingual cortical plate, the distal and mesial confines of the tooth (in other studies the whole crown is sectioned from the roots¹³).
- A small elevator instrument, such as a Warwick James straight elevator, is used to fracture off the crown from the roots. When intentional coronectomy is being undertaken care must be taken not to apply too much torque to the tooth at this point, so that the risk of root mobilization is minimized. If mobilization of the M3M roots occurs, the roots must be elevated. The crown of a mesio-angularly or horizontally impacted third molar may need further sectioning to avoid damage to the lower second molar tooth.
- *If at any time the roots are mobilized they should be removed.*
- A rose-head bur may then be used to remove any enamel spurs and to take the level of the remaining root a few millimetres below the alveolar crestal bone level. Care

- Failed coronectomy 9–38% (mobilization of roots)
- Similar dry socket or infection rate to extraction
- Re-operation rate 0–2%
- Root migration rate 13–33%
- M3M endodontic treatment in addition to coronectomy does not improve success¹⁷

Table 1. The complications reported related to coronectomy.^{5,12–16}

- Patient selection – select only non-compromised patients with good healing potential
- Tooth selection – only select high M3Ms that are vital
- Technique – article highlights some specific technical aspects that will minimize morbidity
- Follow-up patients must be appropriately informed of risks and that they must be able to inform and, if necessary, return to the practitioner if complications arise

Table 2. Coronectomy complications will depend on several factors.

MUST be taken not to encroach on the lingual tissues. The pulp chamber tissue should be left untouched and untreated during smoothing of the root surface in order to maintain vitality of the root. Ideally, there should be alveolar bone above the root edges but this is not always possible where bone levels are absent (for example, the missing lingual plate).

- The area is then closed primarily with resorbable sutures, usually a single suture (4/0 vicryl); more sutures can be used if required.
- The author prefers pre- and post-operative chlorhexidine mouthwash or gel. Antibiotics are not prescribed unless there is a concurrent pericoronitis infection or there is active mucosal infection at surgery.
- Generally, coronectomy patients have less pain than that associated with M3M removal, most likely due to less bone removal.

Post-operatively

Early

Should the patient return with 'dry socket' symptoms, treat as for a dry socket with irrigation using chlorhexidine solution

and placement of a resorbable dressing (*Alvogyl*). If the patient returns with persistent or recurrent infection, then consideration should be given to removing the roots. In the author's experience, two cases have had early post-operative infection with IAN neuritis (intermittent lip paraesthesia resolving with antibiotics) as a result of proximal apical infection to the IAN canal and, in both cases, this resolved with extraction of the infected roots.

Endodontic therapy for coronectomized teeth is not indicated.¹⁸

Late

It is estimated that eruption of the 'coronectomized' roots may occur in 2–5% of cases at 2–5 years. Often, the roots will have erupted away from the IAN canal, thus minimizing IAN morbidity, however, in some cases the root may be intricately involved with the nerve, and careful surgery is required to separate the root from the nerve.¹⁵

Remember that it is possible for any mandibular posterior tooth to be proximal to the IAN. Be aware that any mandibular tooth that is crossing the IAN canal, and displays the radiographic signs, is associated with increased risk of IAN injury. In these circumstances, the patient must be assessed, consented and treated similarly to high risk third molar teeth.

The complications reported related to coronectomy and conditions they depend on are given in Tables 1 and 2.

Conclusion

The prevention of inferior alveolar nerve injuries during third molar surgery may be possible by:

- A clinical decision based on NICE guidelines that the tooth needs to be extracted (ie do not undertake prophylactic surgery unless indicated).
- Using articaine infiltration only technique where possible with rescue inferior dental block with lidocaine 2%.
- Identifying high risk teeth (specific consent) by identifying radiographic risk factors for IAN injury:

- Tooth crossing BOTH lamina dura of IAN canal;
- Juxta-apical area;
- Deviation of canal;
- Narrowing of roots.

If the tooth is in close proximity

to the IAN on plain film then Cone beam CT scanning may further elucidate the relationship between IAN and tooth roots. If the tooth is vital and the patient non-compromised, consider coronectomy of the tooth.

If CBCT confirms that the M3M roots are perforated or 'intertwined' with the IDC then an intentional coronectomy is advised in an appropriate host.

The use of CBCT in these 'high risk' cases may reduce the necessary root retention after coronectomy by over 60%. If a tooth is non-vital, or associated with pathology, then complete tooth removal has to take place and the roots should be sectioned appropriately to minimize trauma to the adjacent IAN. The patient should be warned of an increased risk of permanent (2%) and temporary IAN injury (20%).

If the patient or tooth is compromised, the CBCT scan will enable appropriate planning for removal of the high risk M3M with appropriate consent.

References

1. Howe GL, Poyton HG. Prevention of damage to the inferior dental nerve during the extraction of mandibular third molars. *Br Dent J* 1960; **109**: 355–363.
2. Rood JP, Nooraldeen Shehab BA. The radiological prediction of inferior alveolar nerve injury during third molar surgery. *Br J Oral and Maxillofacial Surg* 1990; **28**: 20–25.
3. Rud J. Third molar surgery perforation of the inferior dental nerve through the root and lingual bone. *Tandlaegebladet* 1983; **87**: 585–588.
4. Rud J. Third molar surgery: relationship of root to mandibular canal and injuries to inferior dental nerve. *Dan Dent J* 1983; **87**: 619–631.
5. Renton T, Hankins M, Sproate C, McGurk M. A randomised controlled clinical trial to compare the incidence of injury to the inferior alveolar nerve as a result of coronectomy and removal of mandibular third molars. *Br J Oral Maxillofac Surg* 2005; **43**(1): 7–12.
6. Tantanapornkul W, Okouchi K, Fujiwara Y, Yamashiro M, Maruoka Y, Ohbayashi N, Kurabayashi T. A comparative study of cone-beam computed tomography and conventional panoramic radiography in assessing the topographic relationship between the mandibular canal and impacted third molars. *Oral Surg Oral Med Oral Pathol Oral Radiol Endod* 2007; **103**(2): 253–259

7. Jhamb A, Dolas RS, Pandilwar PK, Mohanty S. Comparative efficacy of spiral computed tomography and orthopantomography in preoperative detection of relation of inferior alveolar neurovascular bundle to the impacted mandibular third molar. *J Oral Maxillofac Surg* 2009; **67**(1): 58–66.
8. Friedland B, Donoff B, Dodson TB. The use of 3-dimensional reconstructions to evaluate the anatomic relationship of the mandibular canal and impacted mandibular third molars. *J Oral Maxillofac Surg* 2008; **66**(8): 1678–1685.
9. Umar G, Bryant C, Obisesan O, Rood P. Correlation of the radiological predictive factors of inferior alveolar nerve injury with cone beam computed tomography findings. *Oral Surg* 2010; **3**: 72–82.
10. Frafjord R, Renton T. A review of coronectomy. *J Oral Surg* 2010; **3**: 1–7.
11. Yamada T, Ishihama K, Yasuda K, Hasumi-Nakayama Y, Ito K, Yamaoka M, Furusawa K. Inferior alveolar nerve canal and branches detected with dental cone beam computed tomography in lower third molar region. *J Oral Maxillofac Surg* 2011; Jan 20. [Epub ahead of print].
12. O'Riordan BC. Coronectomy (intentional partial odontectomy of lower third molars). *Oral Surg Oral Med Oral Path Oral Radiol Endod* 2004; **98**: 274–280.
13. Pogrel MA, Lee JS, Muff DF. Coronectomy: a technique to protect the inferior alveolar nerve. *J Oral Maxillofac Surg* 2004; **62**: 1447–1452.
14. Hatano Y, Kurita K, Kuroiwa Y, Yuasa H, Arijji E. Clinical evaluations of coronectomy (intentional partial odontectomy) for mandibular third molars using dental computed tomography: a case-control study. *J Oral Maxillofac Surg* 2009; **67**: 1806–1814.
15. Leung YY, Cheung LK. Coronectomy of the lower third molar is safe within the first 3 years. *J Oral Maxillofac Surg* 2012; **70**(7): 1515–1522. doi: 10.1016/j.joms.2011.12.029. Epub 2012 Apr 10.
16. Dolanmaz D, Yildirim G, Isik K, Kucuk K, Ozturk A. A preferable technique for protecting the inferior alveolar nerve: coronectomy. *J Oral Maxillofac Surg* 2009; **67**: 1234–1238.
17. Pogrel MA. An update on coronectomy. *J Oral Maxillofac Surg* 2009; **67**(8): 1782–1783.
18. Sencimen M, Ortakoglu K, Aydin C, Aydintug YS, Ozyigit A, Ozen T, Gunaydin Y. Is endodontic treatment necessary during coronectomy procedure? *J Oral Maxillofac Surg* 2010; **68**(10): 2385–2390. Epub 2010.