



ISSN NO. 2320-5407

Journal Homepage: -www.journalijar.com

INTERNATIONAL JOURNAL OF ADVANCED RESEARCH (IJAR)

Article DOI:10.21474/IJAR01/8067
DOI URL: <http://dx.doi.org/10.21474/IJAR01/8067>



INTERNATIONAL JOURNAL OF
ADVANCED RESEARCH (IJAR)
ISSN 2320-5407
Journal Homepage: <http://www.journalijar.com>
Journal DOI:10.21474/IJAR01

RESEARCH ARTICLE

COMPLICATIONS IN THIRD MOLAR EXTRACTION: MAIN APPROACHES.

Kaue Henrique de Lima Cambauva¹, Idiberto José Zotarelli Filho^{1,2} and Igor Mariotto Beneti^{1,2}.

1. University Center North Paulista (Unorp) Dental School - São José do Rio Preto – SP, Brazil.
2. Post Graduate and Continuing Education (Unipos), Department of scientific production, Street Ipiranga, 3460, São José do Rio Preto SP, Brazil.

Manuscript Info

Manuscript History

Received: 11 September 2018
Final Accepted: 13 October 2018
Published: November 2018

Keywords:-

Third Molar. Extraction. Complications.
Treatments.

Abstract

Introduction:As the removal of the third molar can cause a series of complications, of varying morbidity, some cases having a very radical non-intervention, which is more common complications such as swelling and inflammation, as well as the more complex ones such as mandibular fracture and infections, depending on the cases of some cases may be hospital intervention necessary,

Objective: Was to review the main complications associated with the extraction of third molars and their pre-disposing factors. Major **Considerations:**To avoid such complications should be made a very well detailed planning with a vast anatomical knowledge of the professional and bear in mind that the larger and more complex surgical techniques will be the greater the chances of complications during and after the surgery have a post-operative procedure for each procedure in which it was submitted to all of these complications among others can be avoided with a good postoperative period.

Copy Right, IJAR, 2018,. All rights reserved.

Introduction:-

Third molar surgery is the most common procedure performed by bucomaxillofacial dental surgeons or by professionals without specific specialization [1]. These procedures can cause complications may be linked to the age of the patient as the tooth presents itself in the cavity; lack of anatomical knowledge are some factors that feed the probability of a more serious complication, regardless of the correct complication and prevent it before it happens, being able to be prevented with the control of the operative field, not exaggerating with the applied force, anxiety control of the patient ie once it is identified and must be effectively treated [1].

Thus, the complications that will be mentioned in this work are more focused on the extraction of third molars, but it may occur in extractions in general, once the extraction is indicated and a radiographic clinical examination is indispensable and some cases tomographic exams complementary tests such as blood, for we have an overview of the patient and in what state he presents himself, so that we can close the specific case for the individual [2].

In most cases of complications are associated with the position in which the dental element presents in the buccal cavity [1,2]. Teeth that present as non-erupted do not appear in the oral cavity and are called impacted inclusions are more likely to occur complications [2].

Corresponding Author:-Kaue Henrique de Lima Cambauva.

Address:- University Center North Paulista (Unorp) Dental School - São José do Rio Preto – SP, Brazil.

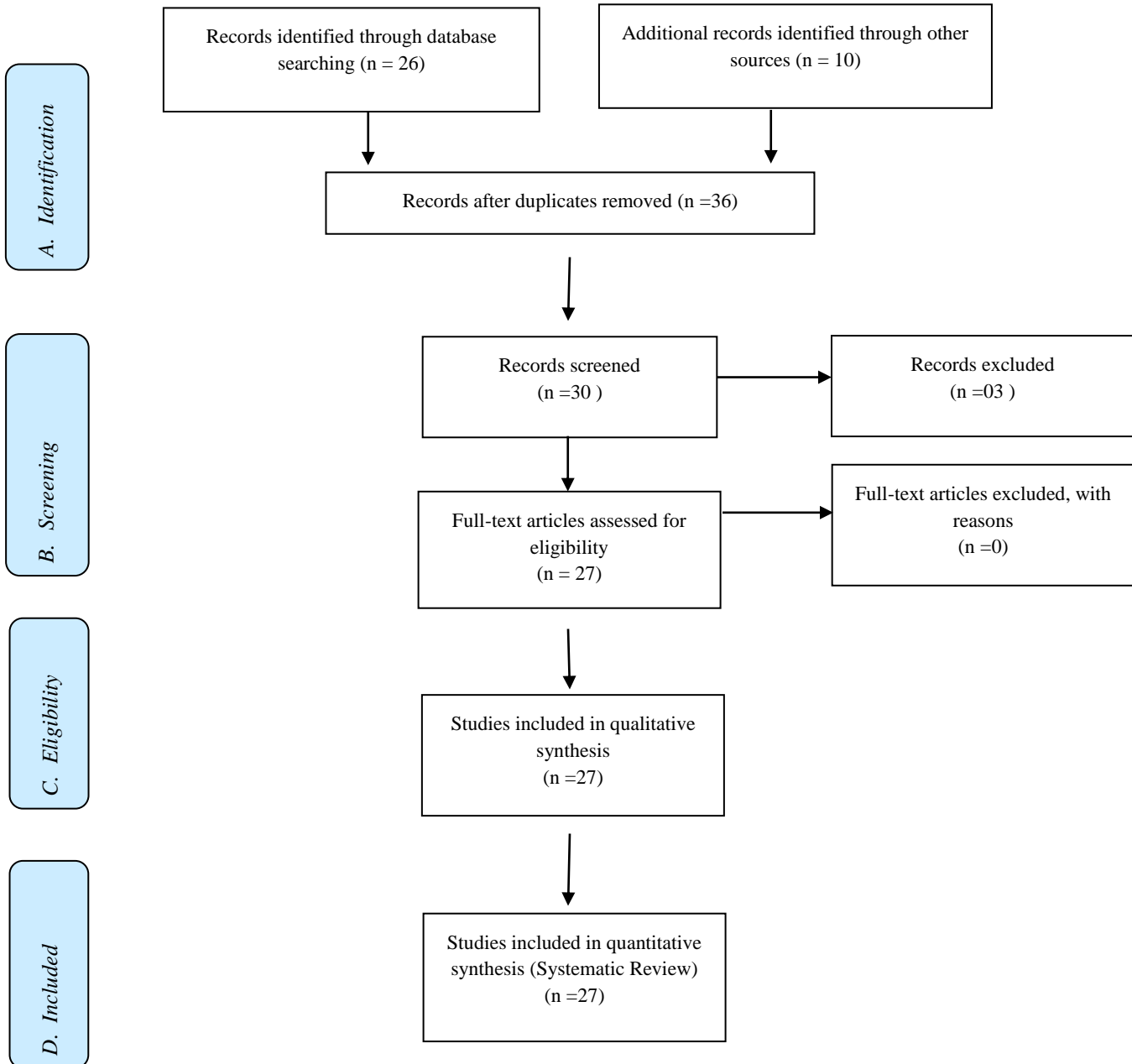
Therefore, the present work had the objective to present the main approaches on the possible complications in the third molar extraction.

Methods:-

Study design

Following the criteria of literary search with the use of the Mesh Terms that were cited in the item below on "Search strategies", a total of 36 papers that were submitted to the eligibility analysis were collated and, after that, 27 studies were selected.

Flow Chart



Search Strategy and Sources of Information

In general, as an example, the search strategy in MEDLINE / Pubmed, Web Of Science, ScienceDirect Journals (Elsevier), Scopus (Elsevier), OneFile (Gale) followed the following steps: - search for mesh terms: *Third Molar. Extraction. Complications. Treatments.*, and use of the bouleanos "and" between mesh terms and "or" among historical findings.

Literature review

The complications that we have in the extraction surgery, which are what we expect to happen are the pain, edema, and tremor despite short duration and a source of discomfort for the patient also to those in which are not more severe complications like excessive bleeding and alveolar fractures [1].

After removal, the pain reaches its peak in the first 12 hours, when the anesthetic effect extinguishes, causing great stress and suffering to the patients and their surroundings [2-5]. The interpretation of the physical and chemical aspects of the noxious style and interaction of it with individual aspects such as mood, pain and a complex multifactorial phenomenon and difficult to be evaluated, in relation to the edemas can be cited that the factors contribute to this sequel is related to the inflammatory process initiated by the surgical act and has its maximum peak at 48 to 72 hours after the surgical act, to decrease the edema the patient should be advised, at the end of the surgical procedure to make compresses with ice packs on the area to help decrease increase the volume and remove discomfort from it [6-10].

However, for the prevention of postoperative edema, no measure is made as to the use of drugs aimed at combating inflammation [11,12]. Therefore, the use of spheroidal anti-inflammatory drugs in the preoperative period together with non-spheroidal anti-inflammatory drugs reduces facial pain and limited mouth opening [13].

Further, trismo is also known as a common complication that is reported by patients who have undergone surgical extraction [14]. Described as muscular pain, due to a myofascial spasm that injures muscle fibers, multiple local anesthetics can cause tourism, especially if it penetrates the masticatory muscle, tourism occurs in more than 50% of the removals of 3° molar in the period of two days after the surgery, having its relevant reduction in 2 days [15-17].

To avoid this inconvenience, less traumatic removals with decreased surgical time may help to resolve tourism or its volume increase, this is because a moist surface transfers lower temperature to the skin, can also be used in the preoperative and anti-corticosteroids non-spheroidal inflammations postoperatively [18-20].

There is a large difference between bleeding and bleeding, bleeding occurs any surgical intervention, but in cases where bleeding becomes excessive in which blood does not coagulate and hemostasis does not occur naturally and the patient is at risk of death in extreme cases [21].]. It is important to prevent excessive blood leakage both for the patient's well-being and for a decrease in the visibility of the operative process, an increase in the edges of the wounds that enhances the development of an infection [22-24].

In the literature some treatments that can be used in the control and treatments of hemorrhages such as fibrin sponge, oxidized cellulose, gelatin sponge, compression on top of the region to avoid all this disorder the ideal and do a preoperative to have the knowledge of the dipsomania of each patient [24,25].

The general hemostatic medication: it is a valuable complement of local methods, in many cases, it becomes indispensable [26]. It is constituted by drugs that act in the coagulation, activating or correcting factors that promote it, or by agents that act on the vessels [26].

The great decrease of blood causes a decrease in tension, resulting in a circulatory deficiency in the tissues. The importance of compensation is to quickly restore the normal volume of mass in large blood loss. The Isotonic solution or Dextrose may be indicated [27]. In emergencies, blood plasma transfusions are now being used because they can be easily administered anywhere, either in hospitals, offices or in the patient's own home. After the emergency period has passed, blood transfusions can be administered later, when necessary [27].

The alveolar bone presents clinically through an exposed alveolus with a defective or totally absent coagulation, with exposed bone walls, it presents itself in two ways to dry violet, moist or suppurative violet [2]. The dry violet and the most stubborn and unpleasant complication erected by intense and prolonged pains and can last up to 15

days, in this case, observed an alveolus exposed without any clot formation with exposure of alveolar bone, with bone walls without any protection and with a white-ivory coloring [2].

Although not very frequent, the complications of removal would be more complex, such as severe high-cost hospital and medication costs and some with irreversible sequelae, some cases requiring the intervention of a maxillofacial surgeon, making it possible to hospitalize, some of which are fractures of maxilla and mandible, infections, nerve damage, tooth dislocations, these are the complications described in the literature [2,3].

Also, nerve injuries can be caused during any surgery to extract any dental element, not only in the third molars, the lesions so many in the upper and lower nerves have their different severities. The most important and complex accidents are those of the inferior and lingual alveolar nerve, due to the proximity of the nerves between the roots of the third molars, the paresthesias are alterations of sensibility that can with direct or indirect traumas like incisions to the nerves by lack of knowledge anatomical, compression and edema [2-4].

To avoid this disorder the anatomical and essential knowledge to prevent the occurrence of the same, the paresthesia presents with the following symptoms, sensation in the region sensation of numbness, tingling and in some cases itching [1,2]. The common lesions are in restored teeth, with great concentration of caries and dislocation of the neighboring tooth, these lesions occur when a very great force is used on the elevators on the surrounding teeth and its roots if diagnosed it must inform the patient and do the procedure soon after surgery [2].

Conclusion:-

To avoid such complications should be made a very well detailed planning with a vast anatomical knowledge of the professional and bear in mind that the larger and more complex surgical techniques will be the greater the chances of complications during and after the surgical act have a proper postoperative to each procedure in which it was submitted to all these complications among others can be avoided with a good postoperative.

References:-

1. Brignardello-Petersen R. Similar anxiety levels and postoperative pain, trismus, and swelling between acupuncture and sham acupuncture in patients undergoing third-molar surgical extraction. *J Am Dent Assoc.* 2018 Nov 19. pii: S0002-8177(18)30689-5.
2. Bhujbal R, A Malik N, Kumar N, Kv S, I Parkar M, Mb J. Comparative evaluation of platelet rich plasma in socket healing and bone regeneration after surgical removal of impacted mandibular third molars. *J Dent Res Dent Clin Dent Prospects.* 2018 Summer;12(3):153-158.
3. Gomes ACA, Silva EDO, Bezerra TP, Pontual MM, Vasconcelos ZR. Terceiros Molares: o que fazer? *Rev Cirur e Traumat Buco-maxilo-facial* 2004; 4(3):137-43.
4. Marzola C. *Retenção Dental.* 2ed. São Paulo: Pancast, 1995.
5. Perry PA, Goldberg MH. Late mandibular fracture after third molar surgery: a survey of connecticut oral and maxillofacial surgeons. *J Oral Maxillofac Surg.* 2000; 58(8):858-61.
6. Peterson L, et al. *Cirurgia oral e maxilofacial.* 4 ed. Rio de Janeiro: Elsevier; 2004.
7. Robinson PP, Smith KG. Lingual nerve damage during lower third molar removal: a comparison of two surgical methods. *Br Dent J* 1996; 180(12):456-61.
8. Muñoz-Guerra MF, González-García R, Capote AL, Escorial V, Gías LN. Subperiosteal abscess of the orbit: an unusual complication of the third molar surgery. *Oral Surg Oral Med Oral Pathol Oral Radiol Endod* 2006 Nov; 102(5): e9-15
9. Paulesini Junior W, Caixeta Neto LS, Leporace AA, Rapoport A. Complicações associadas à cirurgia de terceiros molares: revisão de literatura. *Revista de Odontologia da Universidade Cidade de São Paulo* 2008 maio-ago; 20(2): 181-5
10. Marzola C. *Técnica Exodôntica.* 3ed. São Paulo: Pancast, 2000
11. Kaziro GS. Metronidazole (flagyl) and arnica montana in the prevention of postsurgical complications, a comparative placebo controlled clinical trial. *Br J Oral Maxillofac Surg* 1984; 22(1):42-9.
12. Bamgbonse, BO. Effects of co-administered dexamethasone and diclofenac potassium on pain, swelling and trismus following third molar surgery *Head & Face Medicine* 2005, 1:11:10.1186/1746-160
13. Sursala MS; Blaeser BF; Magalnick D. Third molar surgery and associated complication. *Oral Maxillofacial Surg Clin N Am* 15 (2003) 177-186
14. Capuzzi P; Montebugnoli L; Vaccaro MA. Extraction of impacted third molars. *Surg Oral Med Oral Pathol.*

- 1994;77(4):341-3
15. Silva Netto CR, Bagatin CR, Tambuerus VS, Silva FBR. O efeito da lesão unilateral do nervo lingual sobre a função gustativa: revista da literatura. FOL 1996; 9(2):22-7
 16. Flores JA, et al. Avaliação da prevalência de trismo em pacientes submetidos à exodontia de terceiros molares. RGO 2007; 55(1):17-22.
 17. Gomes ACA. Estudo das lesões nervosas após cirurgia dos terceiros molares inferiores retidos. [Dissertação]. Pernambuco: Universidade de Pernambuco, 2001.
 18. Lizuka T; Tanner S; Berthold H. Mandibular fractures following third molar extraction. A retrospective clinical and radiological study. Int J Oral Maxillofac Surg. 1997;26:338-343
 19. Oliveira R, Blajieski MT, Fernandes LT. Complicações em exodontias de terceiros molares inferiores. UEPG Ci. Biol. Saúde. 2009; 15 (2): 15/22.
 20. Simões GF, Santos PG, Olandoski M, Guarniza O. Análise de acidentes e complicações em cirurgias de terceiros molares inferiores retidos. RSBO centro universitário Positivos. 2005; 2(2): 350/359.
 21. Ricieri BC, Aranega MA, Takahashi A, Lemos RF. Alveolite, ocorrência e tratamento em consultórios odontológicos. Ver. Fac. Odonto. Lins. 2006; 18(1): 233/40.
 22. Andrade CV, Rodrigues MR, Coser CR, Bourguignon FMA. Complicações e Acidentes em cirurgia de terceiros molares. Saber Científico. 2012; 2(1): 27/44.
 23. Araujo C, O, Agostinho F,L, C, Marinho F, R, M, L, revelo S, R, L, Bastos G, E, Silva C, V. Incidência dos acidentes e complicações em cirurgia de terceiros molares. Ver. Odontol. UNESP. 2011; 40 (5): 290/295.
 24. Kato B,R, Bueno L, B,R, Oliveira J,P, Ribeiro C,M, Azenha R, M. Acidentes e complicações associadas à cirurgia de terceiros molares realizadas por alunos de odontologia. Ver. Cir. Traumatol. Buco-Maxilo-Fac. 2010; 10 (4): 45/44.
 25. Cardoso L,C, Ribeiro D, E, Bernini F, G, Freitas S, D, Junior F, O, Santana, E. Abscesso tardio de terceiros molares inferiores. Ver. Cir. Traumatol. Buco-Maxilo-Fac. 2008; 8 (3): 17/24.
 26. Liedke ED. Prevalência das retenções dentárias, em especial dos terceiros molares inferiores. RGO 1977; 4:228-9.
 27. Melzack R, Katz J. Pain measurement in persons in pain. in: Wall PD, Melzack R. Textbook of pain. 3ed. Edinburgh: Churchill Livingstone; 1994.