

Exsanguinating Hemorrhage Following Third Molar Extraction: Report of a Case and Discussion of Materials and Methods in Selective Embolization

Michael Wasson, DDS,* Basavaraj Ghodke, MD,† and
Jasjit K. Dillon, DDS, MD, BDS‡

It is rare in routine oral and maxillofacial surgery that bleeding is encountered in such quantity that it cannot be controlled by local measures. In the instance when these measures do not suffice, the surgeon must be aware of the options available in his or her office and community and the steps required to achieve temporary and permanent hemostasis. As discussed in previous reports, orthognathic, pathologic/oncologic, and temporomandibular joint procedures are the most likely oral and maxillofacial surgical procedures to produce hemorrhage in sufficient quantity to endanger life.¹⁻³ Traditionally, ligation of the ipsilateral external carotid artery superior to the bifurcation of the common carotid artery has been the treatment of choice. With improvements in local and regional emergency transport, increasing numbers of hospitals with interventional radiology (IR) capability, and the improvement of techniques and materials within IR, selective embolization is becoming the modality of choice to manage exsanguinating hemorrhage. The present case illustrates a rare occurrence in a common procedure that resulted in selective

embolization after surgical extraction of a mandibular third molar.

Report of Case

A 60-year-old male physician presented by emergency transport to the Harborview Medical Center emergency department (ED) complaining of uncontrolled hemorrhage after attempted extraction of a mandibular third molar. Accompanying the patient was the oral and maxillofacial surgeon who provided a history of a painful, deeply carious, and vertically oriented bony impacted mandibular left third molar (Fig 1). During attempted surgical extraction under intravenous sedation, the surgeon encountered approximately 1.5 L of blood loss that would not cease with local measures. During transport to the ED, the patient received intraoral packing held by bimanual intra- and extraoral pressure by the accompanying surgeon. Once in the ED, the emergency medicine physician reported a stable intraoral bleed with intraoral packing in place and stable vital signs (blood pressure, 127/76 mm Hg; pulse, 71 beats/min; respiratory rate, 16 breaths/min; temperature, 36.4°C). A complete blood count was obtained and showed normal levels of white blood cells (8.15 cells/ μ L; range, 4.5 to 10,000/ μ L), hemoglobin (13.4 g/dL; range, 12 to 16 g/dL), hematocrit (39%; range, 36% to 50%), and platelets (274 cells/ μ L; range, 100 to 450,000/ μ L). Upon removal of the intraoral packing, the ED physician encountered approximately 500 mL of blood loss before repacking the wound. The oral and maxillofacial surgical service was contacted with the request that the packing not be removed until the patient was in the operating room.

Informed consent was obtained for exploration and debridement of the surgical site, use of hemostatic products, use of blood products, exploration of the neck with ligation, and selective embolization. A coagulation panel was obtained to rule out coagulopathy (partial thromboplastin time 26 s; range 1.025 to 39 s; international normalized ratio, 1.1; range 0.8 to 1.2). The patient was taken to the operating room. Removal of the intraoral packing resulted in approximately 500 mL of blood loss in less than 5 minutes. Selective electrocautery yielded a decrease in bleeding. A 5- × 10-mm perforation of the lingual plate, a 5- × 5-mm perforation on the buccal aspect of the inferior border, and the remaining mesial root were visualized. Attempted removal of the mesial root was unsuccessful

Received from the Department of Oral and Maxillofacial Surgery, University of Washington, Seattle, WA.

*Resident.

†Associate Professor and Director, Neuro-Interventional Radiology, Department of Radiology and Neurological Surgery, Harborview Medical Center, Seattle, WA.

‡Clinical Assistant Professor and Program Director.

This work was presented at the National Meeting of the American Association of Oral and Maxillofacial Surgeons, Philadelphia, PA; 2011.

Address correspondence and reprint requests to Dr Dillon: Department of Oral and Maxillofacial Surgery, University of Washington, 325 Ninth Avenue, Box 359893, Seattle, WA 98104; e-mail: dillonj5@uw.edu

© 2012 American Association of Oral and Maxillofacial Surgeons
0278-2391/12/7010-0\$36.00/0
<http://dx.doi.org/10.1016/j.joms.2012.03.003>

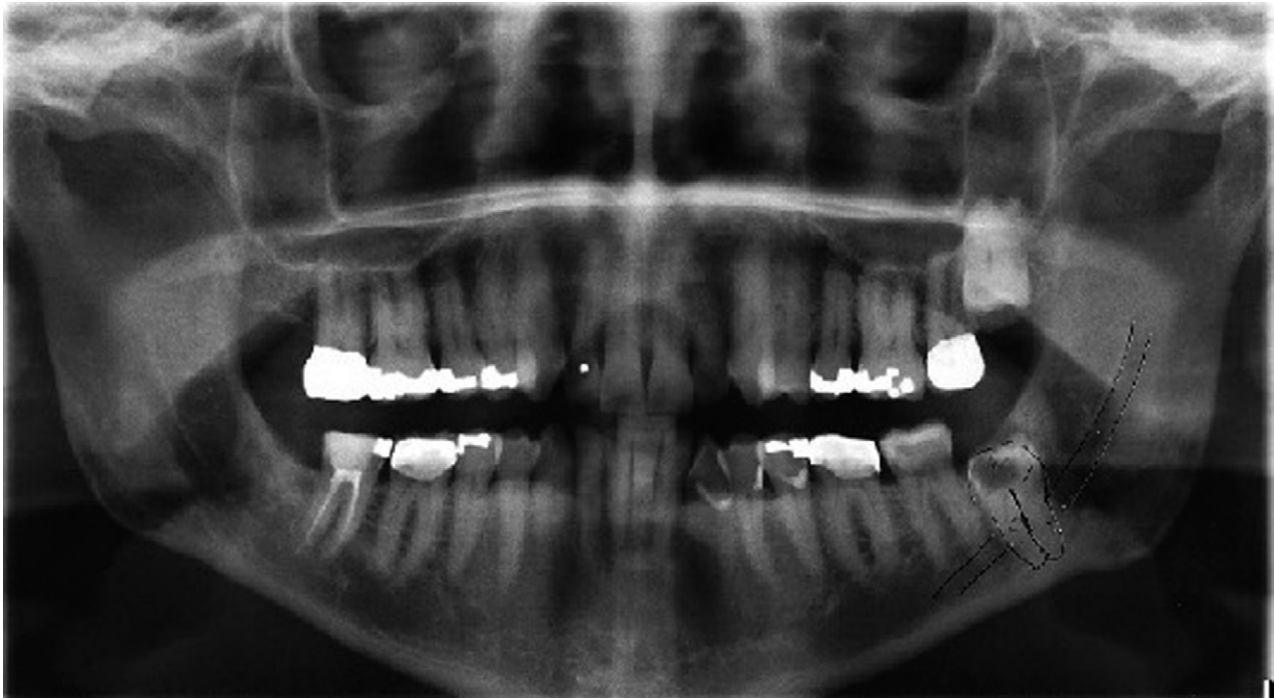

FIGURE 1. Panoramic radiograph displaying a vertically oriented and carious impacted mandibular left third molar.

Wasson, Ghodke, and Dillon. Hemorrhage After Third Molar Extraction. J Oral Maxillofac Surg 2012.

owing to ankylosis. At this time, an intraoperative hematocrit was obtained and determined to be 36%. Although the bleeding had lessened, it appeared to have been controlled too easily given the severity of the bleed. Concerns for an arteriovenous malformation or temporary vasospasm lingered and led to consultation with the

IR service, which recommended an initial computed tomographic angiogram.

The computed tomographic angiogram showed no obvious extravasation, although persistent slow bleeding continued clinically. Discussion between the oral-maxillofacial surgical and IR teams led to the patient being transferred to

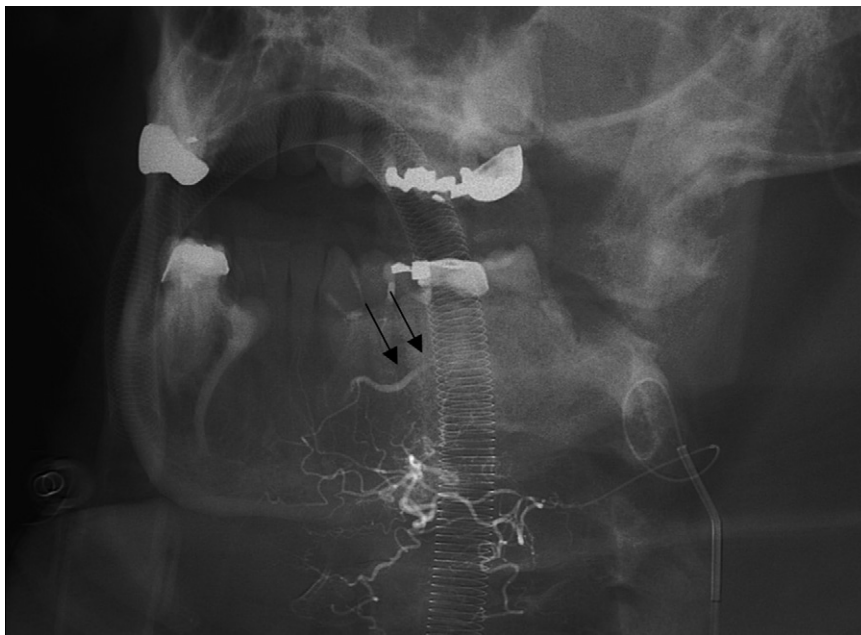


FIGURE 2. Left facial angiogram, anteroposterior oblique view, showing submental collaterals from the facial artery to the inferior alveolar artery (arrows).

Wasson, Ghodke, and Dillon. Hemorrhage After Third Molar Extraction. J Oral Maxillofac Surg 2012.

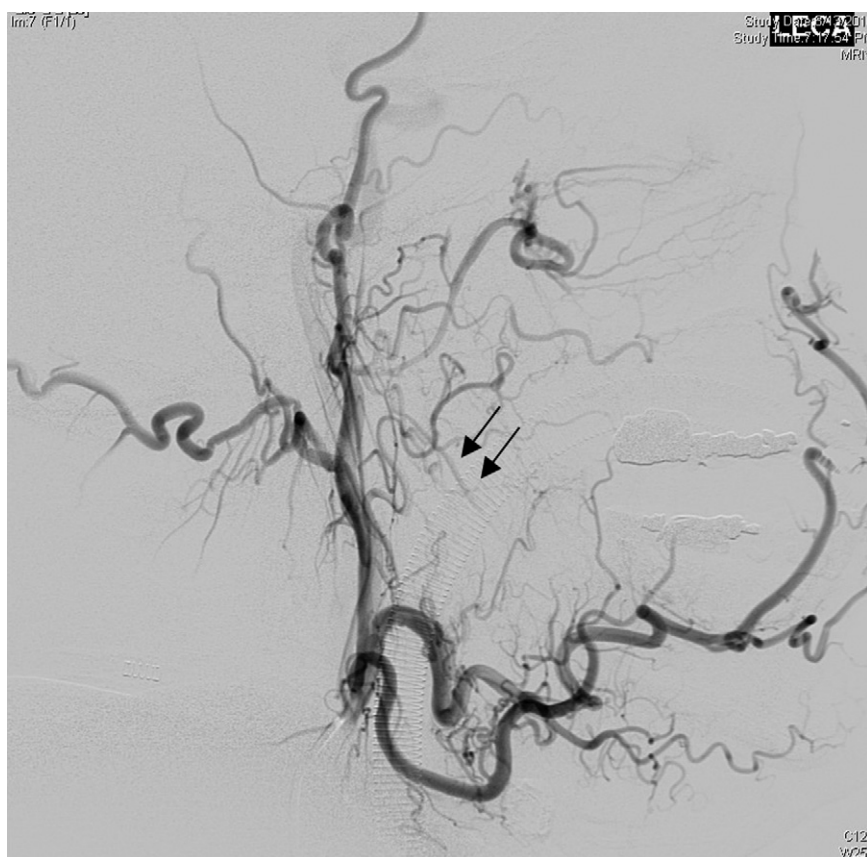

FIGURE 3. Left external carotid angiogram (with digital subtraction angiography), lateral view, showing stagnation of flow in the left inferior alveolar artery (arrows).

Wasson, Ghodke, and Dillon. Hemorrhage After Third Molar Extraction. *J Oral Maxillofac Surg* 2012.

the IR suite for embolization. A left external carotid angiogram showed stagnation in the submental collaterals extending from the facial artery to the inferior alveolar artery. With no flow present in the inferior alveolar artery, the facial artery was suspected as the source of the bleed (Fig 2). Polyvinyl alcohol (PVA) and gelatin sponge microparticles were used to embolize the facial artery. Clinical examination showed decreased but continued bleeding. Further inspection of the stagnant left inferior alveolar artery showed extravasation (Fig 3). Therefore, the artery was embolized with PVA and 25% *n*-butyl cyanoacrylate (NBCA; Trufill Liquid embolic system Cordis, Miami, FL; Fig 4). Hemostasis was confirmed clinically and the surgical site was closed. Per protocol, the patient was transferred to the intensive care unit for intravascular sheath precautions, monitored overnight, and discharged the following day. Postoperative laboratory results immediately after embolization showed a hemoglobin of 10.5 g/dL and a hematocrit of 31%, with slight decreases to 9.6 g/dL and 28% the following morning. Also on the following morning, the patient reported intact bilateral lingual nerve sensation. Although directional sensation was intact, the patient did complain of paresthesia in the distribution of the left inferior alveolar nerve. The patient refused further follow-up for this at Harborview Medical Center, preferring to see the referring oral and maxillofacial surgeon on an as-needed basis. To date per discussion with his oral and maxillofacial surgeon, he has not

returned for further consultation and has not had further issues with the remaining mesial root.

Discussion

Selective embolization has many uses in head and neck surgery, including emergency occlusion of vessels to initiate hemostasis, decrease of blood flow before surgery, palliative occlusion of feeding vessels to produce tumor necrosis, and presurgical occlusion of vascular malformations as an attempted cure or an attempt to minimize blood loss during surgical treatment. Embolization relies on certain hemodynamic principles to be effective. The occlusion of capillaries and precapillary arteries 10 to 150 μm in diameter causes necrosis of tissue in the occluded territory because minimal collateral circulation is present at the capillary level. Precapillary arteries 150 to 600 μm in diameter have adequate proximal collateral vessels.⁴ The collateral circulation is sufficient to prevent necrosis of the supplied tissue; however, the decrease in perfusion pressure created by primary vessel occlusion often is sufficient to lead to hemostasis. These

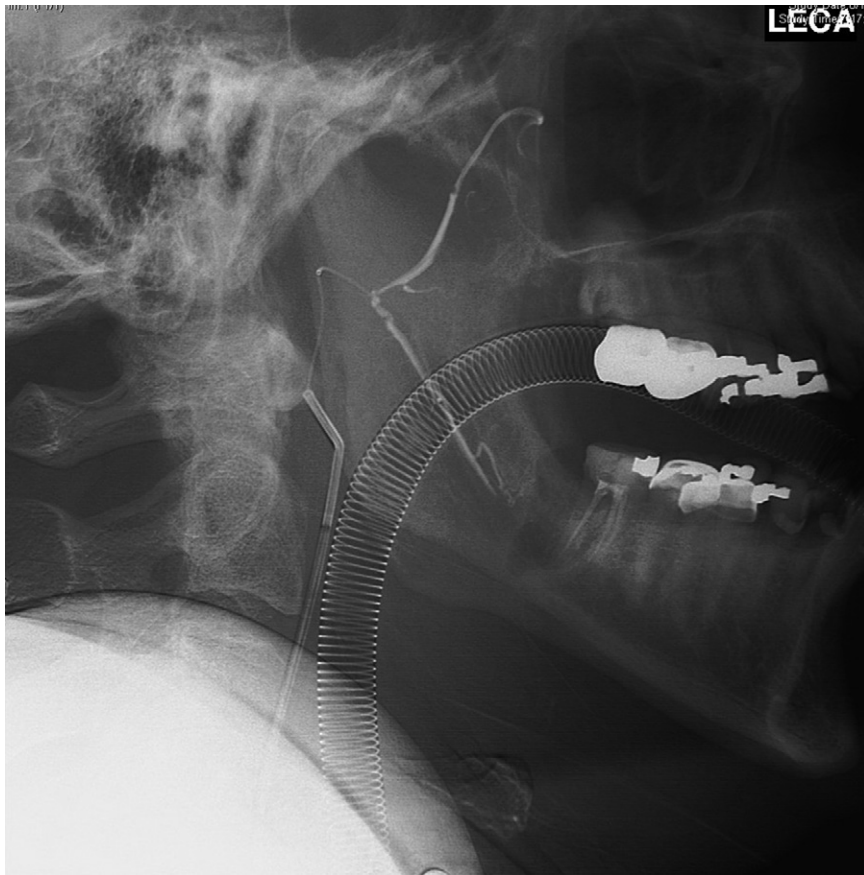


FIGURE 4. N-butyl-2-cyanoacrylate embolization of the left inferior alveolar tributary, leading to a decrease in clinical hemorrhage.

Wasson, Gbodke, and Dillon. *Hemorrhage After Third Molar Extraction*. *J Oral Maxillofac Surg* 2012.

principles are often used in vascular malformations (proximal vessel occlusion or intralumen occlusion) for hemorrhage that cannot be controlled by local measures or in the coagulopathic patient.

For neoplasms, the goal of preoperative embolization is to obliterate vascular neoplasms with preservation of the blood supply to surrounding tissues or to devitalize the tumor tissue in a nonvascular tumor. Tumor embolization can shorten the operating time, aid in the identification of surgically important structures, provide nearly bloodless tumor exposure, and decrease complications and recurrences. In incurable tumor embolization, decreases in size, local pain, local nerve compression, and functional restrictions can be achieved, although often are restricted to only a few months because of the development of resistant tumor cells.

Numerous materials have been used for selective embolization, including PVA particles, NBCA, ethyl vinyl alcohol copolymer suspended in dimethyl sulfoxide (Onyx, EV3, Irvine, CA), platinum microcoils, concentrated alcohol, and gelatin sponge particles. PVA particles are not permanent (vessel recanalization usually occurs within a few weeks) and range

from 45 to 1,000 μm in diameter.⁵ NBCA is a permanent embolization material used widely in IR. Although it is highly technique sensitive, it is becoming the material of choice in many circumstances, especially in patients with coagulopathy. NBCA is not visible under fluoroscopy without the addition of lipiodol and/or tantalum powder and requires a varying, but precise, mixture of NBCA and lipiodol depending on the desired time/distance before polymerization. NBCA also has the potential for intravascular gluing and thus requires rapid withdrawal of the microcatheter after delivery. Ethyl vinyl alcohol (Onyx) is a liquid embolic agent that is radiopaque because of suspended tantalum particles. It is a nonadhesive agent causing rapid hemostasis when injected into a vessel. It has advantages over NBCA because the compound can be injected slowly through microcatheters without fear of being glued in place. Platinum microcoils constitute another permanent embolization material that is placed within a vessel lumen using a guidewire or fluid pressure. These coils are suitable for arresting bleeds directly off large-caliber branches and allow placement at the proximal and distal aspects of the bleed, allowing for vessel occlusion.⁵ Concentrated

Table 1. COMPARISON OF HEMOSTATIC RATES AND TREATMENT TIMES OF EMBOLIZATION MATERIALS

	Primary Hemostatic Rate	Recurrent Hemorrhage Rate	Average Treatment Time (min) (Range)
Gelatin sponge particles	67% (18/27)	23% (3/13)	25 (6-48)
Platinum microcoils	80% (16/20)	0% (0/15)	37 (17-86)
NBCA	100% (16/16)	0% (0/15)	9 (3-16)

Abbreviation: NBCA, *n*-butyl cyanoacrylate.

Wasson, Ghodke, and Dillon. Hemorrhage After Third Molar Extraction. *J Oral Maxillofac Surg* 2012.

alcohol has toxic effects on vessel walls that lead to occlusion. Gelatin sponge particles constitute a temporary material used mostly for distal bleeding sites inaccessible to the microcatheter or in patients with multiple bleeding sites requiring rapid hemostasis.

Multiple studies have been performed comparing the quality, durability, and technique sensitivity of embolization materials. One particular study compared the primary hemostatic rate, secondary hemostatic rate (hemostatic rate using the material as a retreatment option after the failure of a previous material), and treatment times of gelatin sponge particles, platinum microcoils, and NBCA in patients with coagulopathy (defined as international normalized ratio >1.5 or platelet count <5 × 10⁴/μL).⁵ The study concluded that NBCA had the fastest treatment time (9 min) and a 100% success rate in primary and secondary hemostatic rates, whereas gelatin sponge particles had the slowest primary (67%) and secondary (23%) hemostatic rates and an intermediate treatment time of 25 minutes. Platinum microcoils had the longest treatment time (37 min), but had an 80% primary hemostatic rate and a 100% secondary hemostatic rate (Table 1).

As the materials and methods in selective embolization continue to improve, better and faster results are being obtained. However, there is no ideal agent for all circumstances and all levels of experience within IR. As previously mentioned, NBCA is very technique sensitive because of its rapid polymerization and potential for intravascular gluing. Ethyl vinyl alcohol (Onyx) has toxicity related to dimethyl sulfoxide, which can cause vasospasm.⁶ Concentrated

alcohol carries a risk of local necrosis and transcapillary passage to the venous system. Platinum microcoils rarely provide complete occlusion of high-flow vessels. As reported in a previous study,⁵ gelatin sponge particles may not provide adequate results in all situations. Despite its imperfections, selective embolization has proved to be an effective treatment in many conditions and circumstances, and with recent advances in materials, methods, and research, its uses and efficiency will only continue to expand.

The variables involved in the decision to ligate the external carotid artery or selectively embolize involved vessels have been discussed previously and are not the subject of this study.⁷ In brief, the skill of the surgeon and the availability of a qualified interventional radiologist are often the determining factors in this decision. If the 2 options are feasible, as in the present case, decreased bleeding from the collateral circulation can be associated with selective embolization, making it a more effective means of hemostasis.⁸ In the event embolization is not successful, ligation of the external carotid artery and/or other vessels may be completed, whereas the reverse is not possible. These 2 factors make selective embolization the logical first-line therapy for hemorrhage that cannot be controlled by local measures.

References

1. Lanigan DT, West RA: Management of postoperative hemorrhage following the Le Fort I maxillary osteotomy. *J Oral Maxillofac Surg* 42:367, 1984
2. Lanigan DT, Hey J, West RA: Hemorrhage following mandibular osteotomies: A report of 21 cases. *J Oral Maxillofac Surg* 49:713, 1991
3. Oh JS, Kim SG, Kim HK, et al: Massive hemorrhage following bilateral sagittal split ramus osteotomy: A case report. *J Oral Maxillofac Surg* 67:895, 2009
4. Turowski B, Zanella FE: Interventional neuroradiology of the head and neck. *Neuroimaging Clin N Am* 13:619, 2003
5. Yonemitsu T, Kawai N, Sato M, et al: Evaluation of transcatheter arterial embolization with gelatin sponge particles, microcoils, and *n*-butyl cyanoacrylate for acute arterial bleeding in a coagulopathic condition. *J Vasc Interv Radiol* 20:1176, 2009
6. Bulent B, Oruckaptan HH, Hazer BD, et al: Evaluation of the toxicity of onyx compared with *n*-butyl 2-cyanoacrylate in the subarachnoid space of a rabbit model: An experimental research. *J Neuroradiol* 52:125, 2010
7. Bouloux GF, Perciaccante VJ: Massive hemorrhage during oral and maxillofacial surgery: Ligation of the external carotid artery or embolization? *J Oral Maxillofac Surg* 67:1547, 2009
8. Okada S, Ohta Y, Suwa F, et al: Experimental ligation versus embolization of the external carotid artery: A comparative hemodynamics study. *J Osaka Dent Univ* 30:23, 1996