

# Coronectomy of the Mandibular Third Molar: A Retrospective Study of 185 Procedures and the Decision to Repeat the Coronectomy in Cases of Failure

Boaz Frenkel, DMD,\* Navot Givol, DMD,† and Yitzhak Shoshani, DMD‡

**Purpose:** A prevalent complication associated with mandibular third molar extraction is inferior alveolar nerve (IAN) injury. This study evaluated the success rate of coronectomy and, in the event of failure of the procedure, retreatment.

**Patients and Methods:** One hundred seventy-three patients underwent 185 coronectomy procedures of the mandibular third molar to prevent IAN injury. The coronectomy was performed along the cemento-enamel junction. Residual roots were trimmed 3 to 4 mm below the crest margin. No pulp treatment was performed and the roots were left vital. A postoperative orthopantomogram was recorded immediately after the procedure or at follow-up 1 month later. Two additional orthopantomographic views were taken at 6- and 12-month follow-up appointments. Statistical analyses were performed to assess differences in root migration, pain, wound healing and failure by age, gender, and time elapsed from coronectomy. Statistical data were considered significant at a *P* value less than .05.

**Results:** Statistical differences in the migration of residual roots from 6 to 12 months were found. Migration of the roots was found in younger patients. In a total of 10 cases of failure, 4 were treated with repeat coronectomy. The other 6 cases were treated with reoperation (ie, removal of residual roots).

**Conclusion:** Immediate postoperative radiographic imaging is recommended, as well as, follow-up evaluation 12 months after surgery. In addition, repeat coronectomy is recommended for cases in which enamel retention is diagnosed to prevent residual roots from becoming infected.

© 2015 American Association of Oral and Maxillofacial Surgeons  
*J Oral Maxillofac Surg* 73:587-594, 2015

Third molar surgery is the most common oral surgical procedure, with a prevalence of 35.9 to 58.7%.<sup>1,2</sup> The complication of most concern associated with mandibular third molar extraction is inferior alveolar nerve (IAN) injury. The frequency of IAN injury is variable and ranges from 0.4 to 8.4%.<sup>3</sup> The signs of an IAN injury are anesthesia, paresthesia, or dysesthesia of the lower lip and gingiva. There are 5 radiographic signs at orthopantomographic imaging that can indicate close proximity of the roots to the IAN.<sup>4</sup>

These signs correlate with the root proximity to the IAN diagnosed at cone-beam computed tomography (CBCT) at a rate of 88%.<sup>5</sup>

Coronectomy was first introduced by Knutsson et al<sup>6</sup> in 1989 as an alternative extraction technique to prevent IAN injury in cases of root proximity to the IAN or complicated root anatomy of the mandibular third molar, and solve the problem of pericoronitis. Pogrel et al<sup>7</sup> described the surgical technique as a procedure that aims to extract only

\*Oral and Maxillofacial Specialist, Department of Oral and Maxillofacial Surgery, Rambam Medical Center, Haifa, Israel.

†Oral and Maxillofacial Specialist, Department of Oral and Maxillofacial Surgery, Sheba Medical Center, Ramat Gan, Israel.

‡Oral and Maxillofacial Specialist, Department of Oral and Maxillofacial Surgery, Sheba Medical Center, Ramat Gan, Israel.

Conflict of Interest Disclosures: None of the authors reported any disclosures.

Address correspondence and reprint requests to Dr Frenkel: Rambam Medical Center, Ha'aliya Hashniya Street, Haifa, Israel; e-mail: [dr.boazfrenkel@gmail.com](mailto:dr.boazfrenkel@gmail.com)

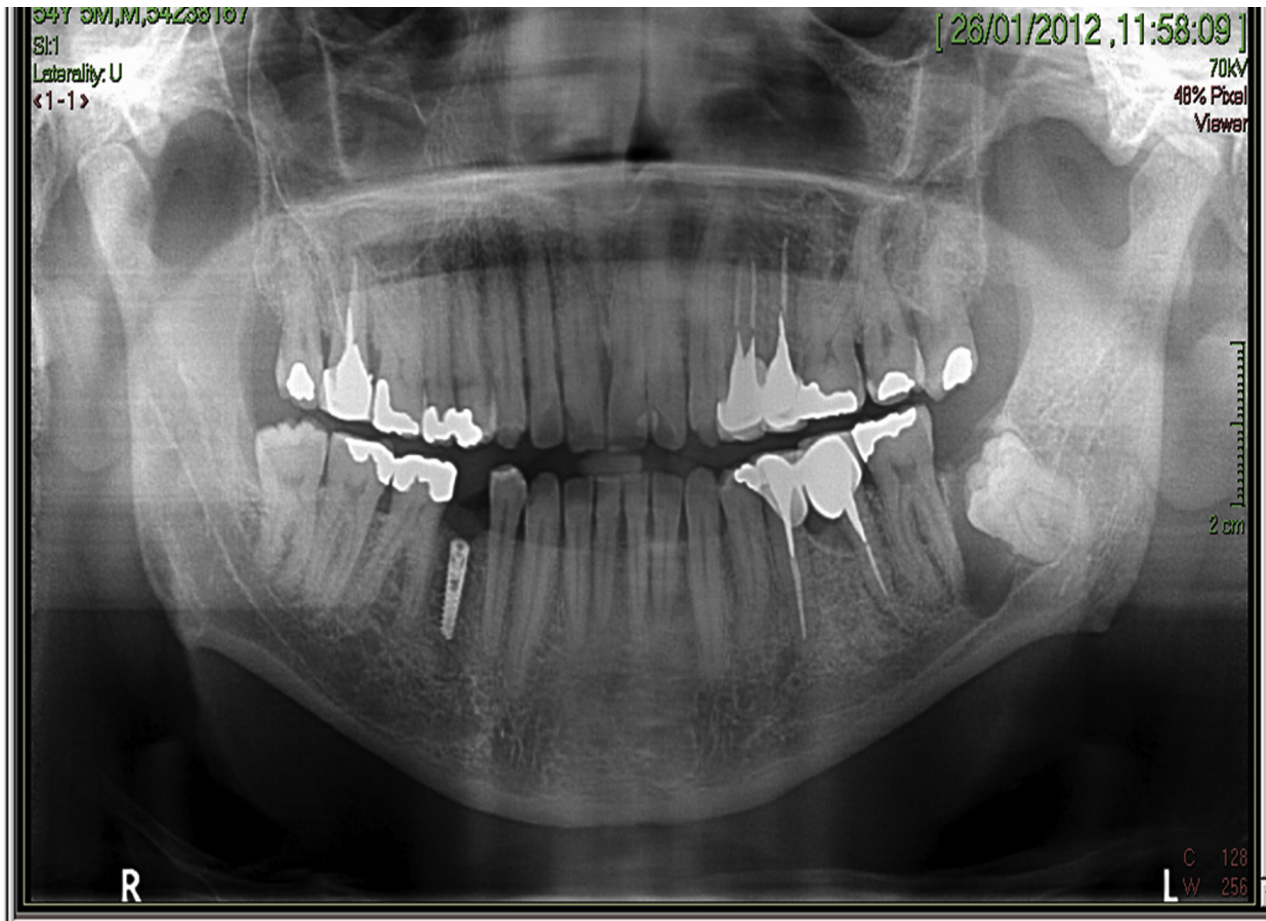
Received July 29 2014

Accepted October 6 2014

© 2015 American Association of Oral and Maxillofacial Surgeons

0278-2391/14/01610-3

<http://dx.doi.org/10.1016/j.joms.2014.10.011>



**FIGURE 1.** Patient 2 before coronectomy.

*Frenkel, Givol, and Shoshani. Coronectomy of Mandibular Third Molar. J Oral Maxillofac Surg 2015.*

the crown of the mandibular third molar and leave the roots intact. The few complications associated with coronectomy are often of a short-term nature, such as postoperative infection, dry socket, and pain, that are treated with antibiotics and analgesic medication.<sup>1,3,8</sup> Other complications are unsatisfactory healing and root eruption into the oral cavity.<sup>1,3,8</sup> Inadequate healing can result from enamel retention on the root surface.<sup>9</sup> Coronectomy failure is usually treated with reoperation, that is, removal of the residual roots.<sup>9,10</sup> To the best of the authors' knowledge, an examination of repeat coronectomy has not been conducted. In the present study, repeat coronectomy after failure was followed by normal healing.

## Patients and Methods

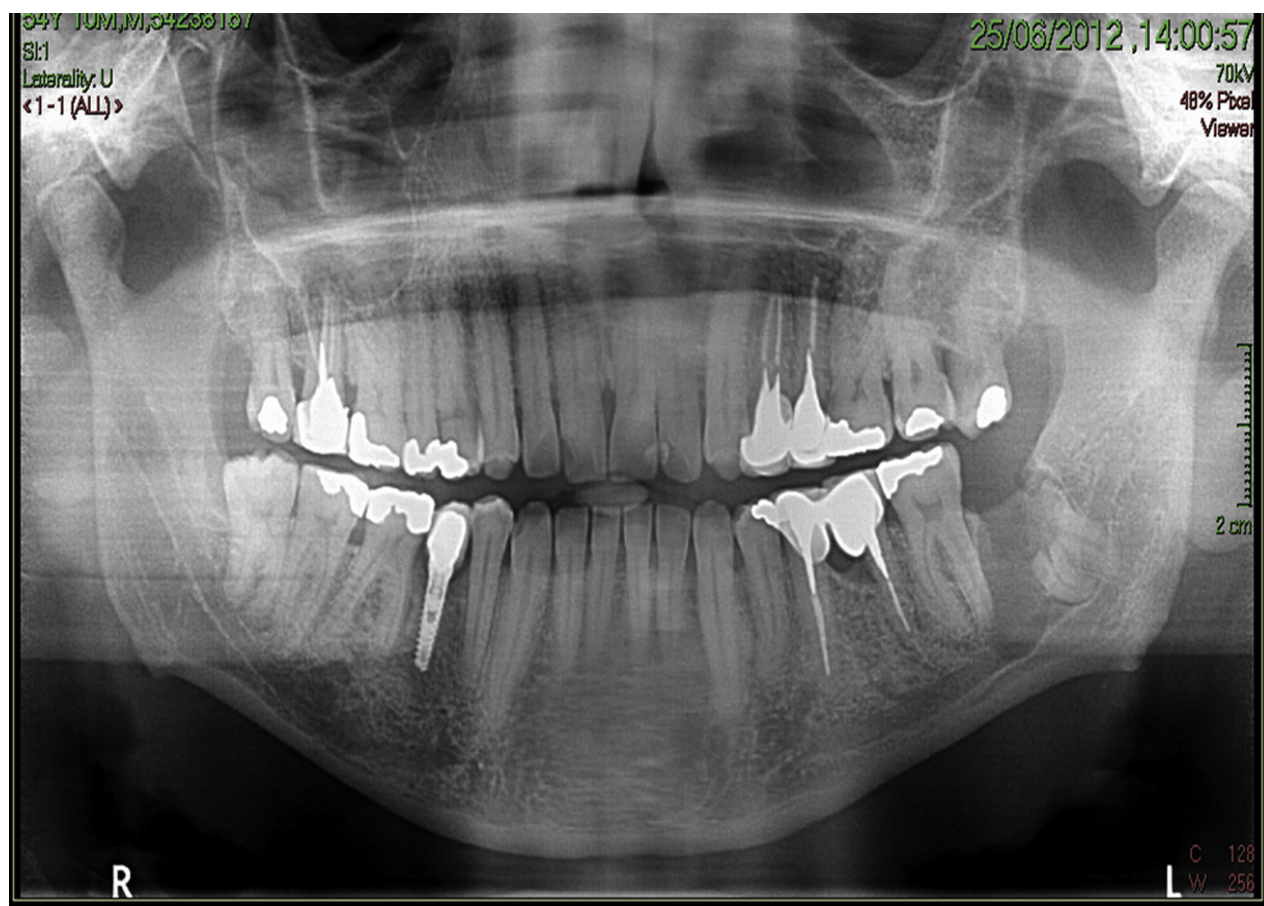
This research was approved by the institutional review board of the Sheba Medical Center (9947-12-SMC; Ramat Gan, Israel). Patients' informed consent was not required owing to the retrospective nature of this study.

## PATIENTS

To prevent IAN injury, 173 patients underwent 185 coronectomy procedures of the mandibular third molar from December 2008 to October 2012 at the Department of Oral and Maxillofacial Surgery, Sheba Medical Center. In this study, coronectomy was performed when orthopantomographic imaging indicated close proximity of the roots of the mandibular third molar to the IAN or when the patient was very anxious owing to the potential risk of IAN injury. The most prevalent diagnosis leading to mandibular third molar extraction was pericoronitis.

The radiographic signs by orthopantomographic imaging implied close proximity of the third molar root to the IAN and were consistent with the criteria of Rood and Shehab<sup>4</sup>:

1. darkening of the root
2. interruption and loss of the white line representing the borders of the inferior alveolar canal
3. diversion of the inferior alveolar canal by the roots
4. abrupt narrowing of the root
5. deflected roots



**FIGURE 2.** Patient 2 1 month after coronectomy.

*Frenkel, Givol, and Shoshani. Coronectomy of Mandibular Third Molar. J Oral Maxillofac Surg 2015.*

Subsequent CBCT imaging of some cases confirmed this close proximity.

#### SURGICAL PROCEDURE

All surgical procedures were performed according to standard protocol. Coronectomy was performed under local anesthesia (lidocaine 2% with 1:100,000 adrenalin). A buccal mucoperiosteal flap with a releasing incision was raised and the lingual aspect was protected subperiosteally with a lingual retractor. The surrounding bone was removed with a bur to the level of the cemento-enamel junction, where the coronectomy was performed. Residual roots were trimmed 3 to 4 mm below the crest margin. No pulp treatment was performed and the roots were left vital. Primary wound closure was conducted. Postoperative antibiotic was prescribed (amoxicillin 1.5 g/day for 1 week or clindamycin 600 mg/day for 1 week).

#### MEASUREMENT OF OUTCOMES

The data of 173 patients who underwent coronectomy from December 2008 through October 2012 was collected retrospectively. The standard protocol

included evaluation of the residual roots and surrounding tissue 1, 6, and 12 months after the coronectomy procedure. Patients were monitored by orthopantomographic imaging after surgery or 1 month later (Figs 1-5). At least 2 orthopantomograms were recorded at follow-up appointments 6 and 12 months after surgery.

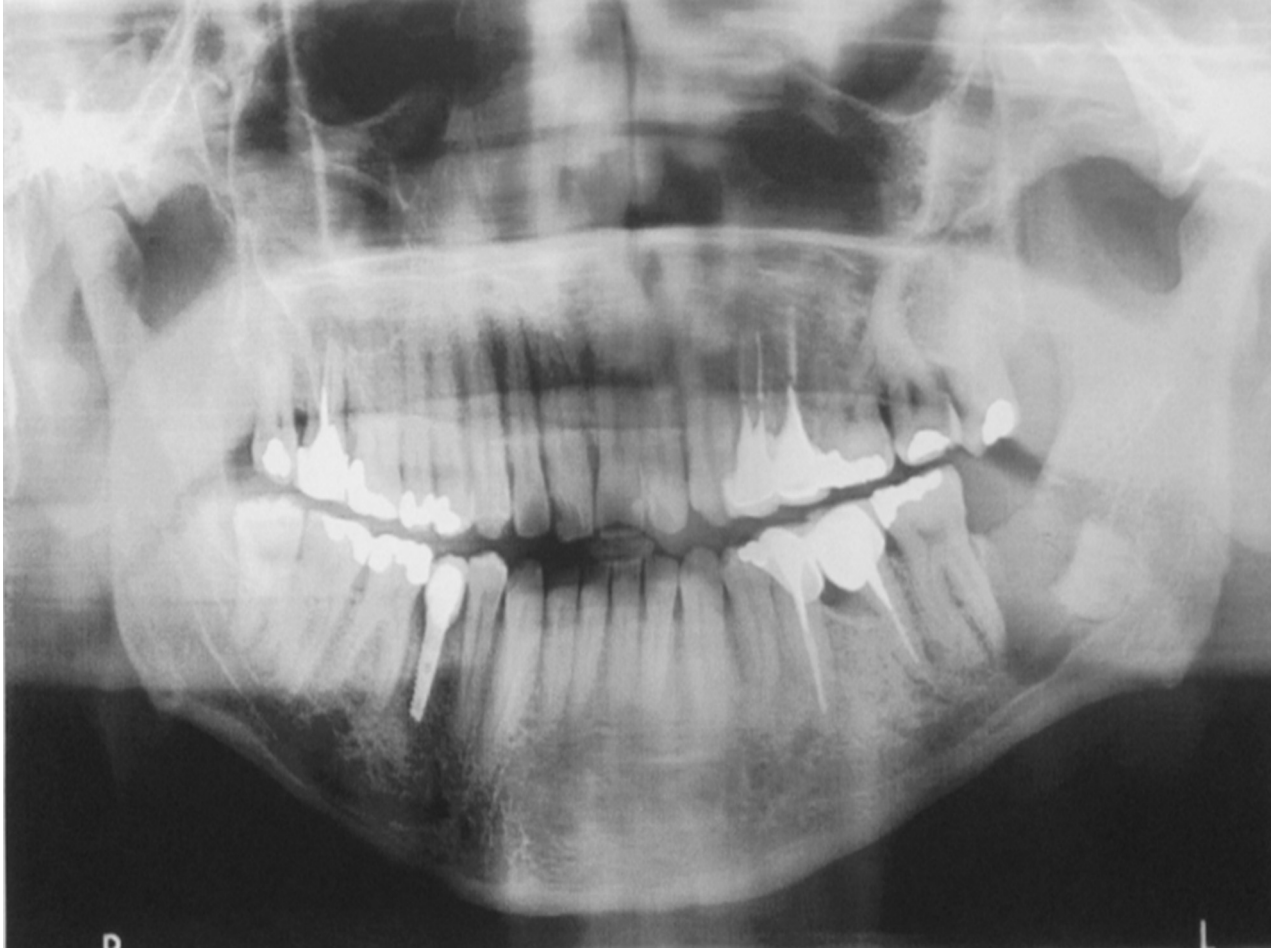The following 4 binary (yes vs no) parameters were evaluated 1 month after coronectomy:

- wound healing
- pain
- infection
- sensory alteration

Six and 12 months after coronectomy, the first 3 parameters and 4 additional parameters were evaluated:

- gingival pocket distal to mandibular second molar (millimeters)
- bone formation coronal to residual roots (yes vs no)
- migration of residual roots measured by the distance of the root apex from the inferior alveolar canal along the long axis of the original tooth (millimeters)





**FIGURE 3.** Patient 2 immediately after repeat coronectomy.

*Frenkel, Givol, and Shoshani. Coronectomy of Mandibular Third Molar. J Oral Maxillofac Surg 2015.*

- action taken: reoperation versus repeat coronectomy versus follow-up only

#### STATISTICAL ANALYSIS

Statistical analyses were performed to analyze differences in root migration, pain, wound healing and failure by age, gender, and time elapsed from procedure. SPSS 21.0 (SPSS, Inc, Chicago, IL) was used to analyze the data. Outcomes with a confidence level of 5% were considered statistically significant.

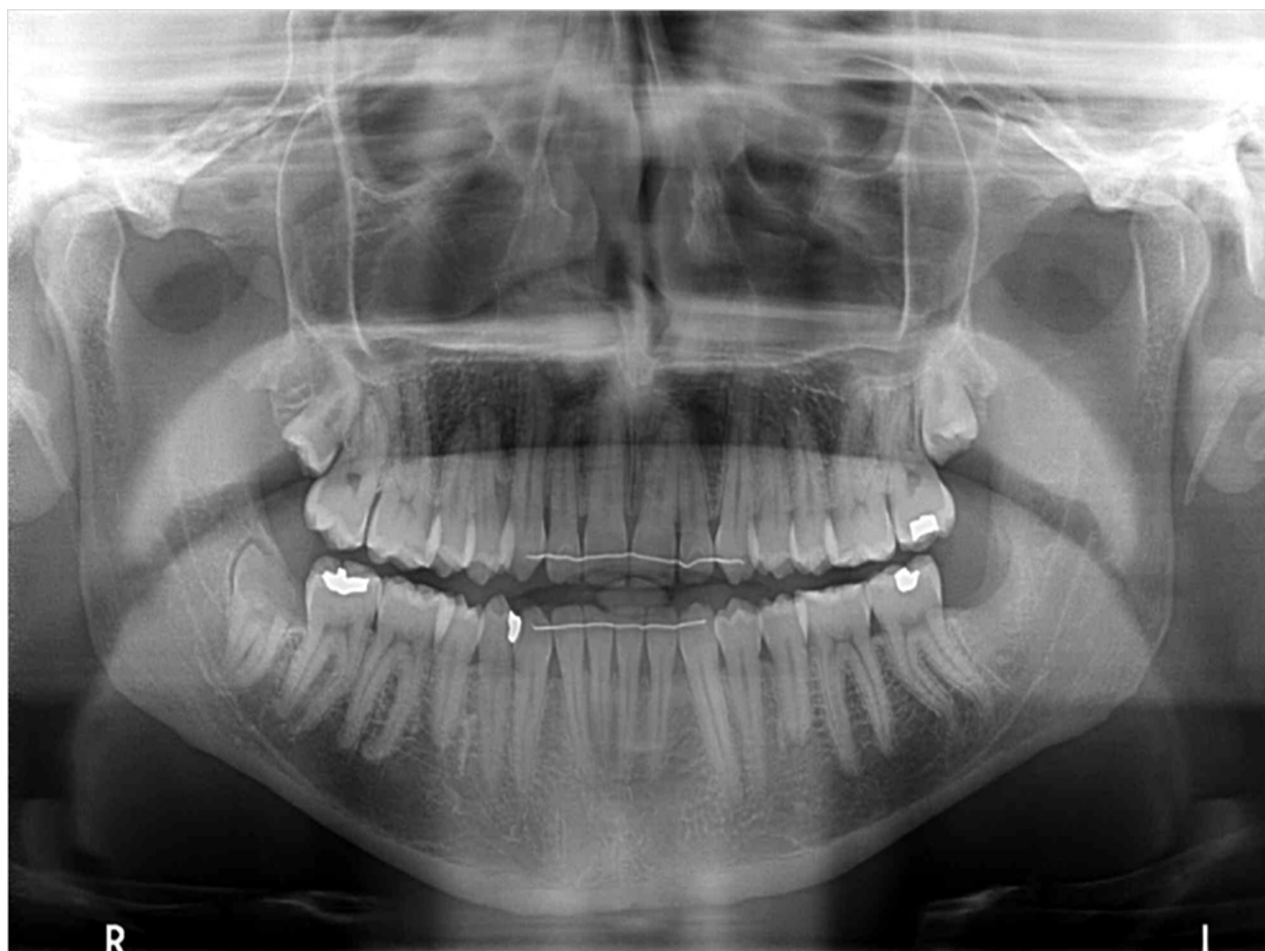#### Results

Patient demographic characteristics are presented in [Table 1](#). In total, 173 patients underwent 185 coronectomy procedures of mandibular third molars. Patient age ranged from 17 to 65 years. Thirteen patients (7%) underwent coronectomy of the 2 mandibular third molars.

[Table 2](#) presents details of the first follow-up that took place 4 weeks after the surgical procedure. Only

102 teeth could be examined because some patients did not present for follow-up sessions. Fifty-six coronectomy sites exhibited a good healing process as indicated by closed gingiva, whereas 46 coronectomy sites showed evidence of sinus opening. Sixteen patients (15%) complained of pain 1 month after surgery, whereas 85 (85%) patients were pain free. Inflammatory processes were viewed in 15 coronectomy sites (14%). Only 1 patient reported hypoesthesia of the lower lip. Three coronectomy procedures were considered failures and the residual roots were removed (reoperation) owing to an inflammatory process with pus discharge. In 3 other cases, a normal healing process followed a repeat coronectomy performed after the retention of enamel was diagnosed. A positive correlation between the evaluation time and the healing process of the coronectomy sites was determined.

[Table 2](#) lists details of the second follow-up that took place approximately 6 months after surgery. Not all patients kept this appointment, so only 64 teeth were examined. Most coronectomy sites showed normal healing (closed gingiva), whereas 5 (7%) of



**FIGURE 4.** Patient 3 1 month after coronectomy.

*Frenkel, Givol, and Shoshani. Coronectomy of Mandibular Third Molar. J Oral Maxillofac Surg 2015.*

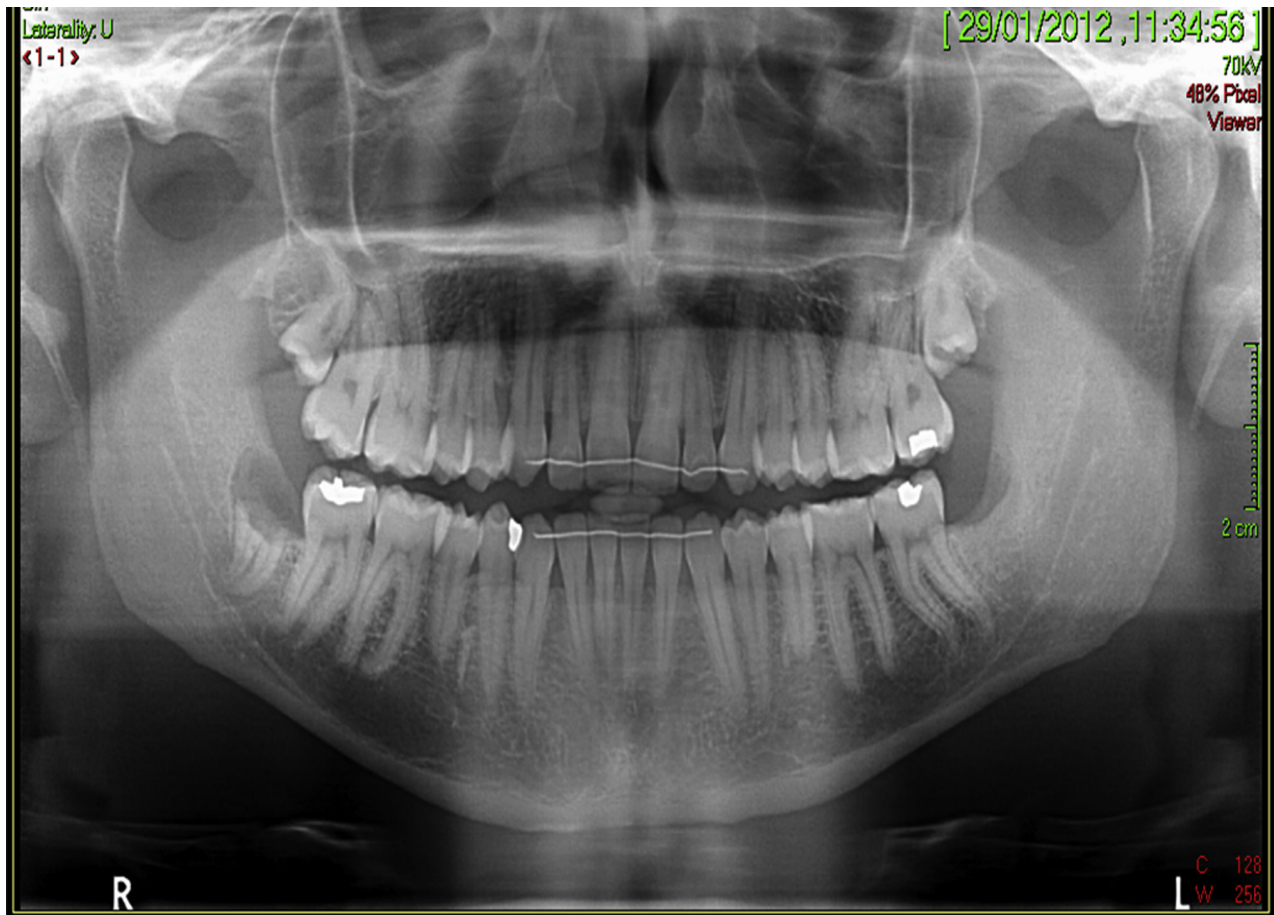
the coronectomy sites showed unsatisfactory healing with clinical evidence of sinus opening. Sixty-one patients (95%) were pain free, whereas 3 patients complained of pain, indicating inflammatory processes at the coronectomy site. The average pocket measurement, distal to the lower second molar, was 4 mm. Pocket measurements of at least 5 mm were found at 14 coronectomy sites. At orthopantomographic imaging at 6 months, 5 (8%) coronectomy sites exhibited no bone formation coronal to residual roots. Two thirds of the residual roots had migrated (average migration distance, 2.2 mm). Total removal of the residual roots was conducted at 1 coronectomy site owing to unexplained pain, and at another site coronectomy was repeated and residual enamel was removed followed by normal healing.

Table 2 lists details of the third follow-up that took place approximately 12 months after surgery. Of the 34 teeth that were examined, normal healing was observed at 32 sites (closed gingiva), whereas 2 failed to heal (there was clinical evidence of sinus opening). All patients except 1 were pain free. There were no

inflammatory processes at the coronectomy sites. The average pocket measurement, distal to the lower second molar, was 3.8 mm. The 12-month orthopantomogram displayed only 2 coronectomy sites that did not show bone healing coronal to the residual roots. Approximately two thirds of residual roots had migrated (average migration distance, 3.2 mm). Two coronectomy sites underwent total removal of the residual roots. One case was performed owing to unexplained pain and the other owing to residual root eruption into the oral cavity.

There were statistical differences in the migration of residual roots after 6 and 12 months (effect size by Cohen  $d$ , 0.94). The results of root migration were examined using analysis of variance and the Pearson correlation tests, and a negative correlation was found between age and root migration only at the second follow-up (the younger the patient, the farther the migration). Pocket depth did not predict coronectomy failure.

Patients were categorized into “no-migration” (migration, 0 mm) and “migration” (migration, >0; Table 3) groups. At 6-month follow-up, the average age of the no-migration group was older than that of



**FIGURE 5.** Patient 3 immediately after repeat coronectomy.

*Frenkel, Givol, and Shosbani. Coronectomy of Mandibular Third Molar. J Oral Maxillofac Surg 2015.*

the migration group (39.6 vs 24.5 years, respectively;  $P < .05$ ). Similar significant results were obtained after the 12-month evaluation (37.5 yr for no-migration group vs 24.5 yr for migration group;  $P < .05$ ). The failure cases are listed in [Table 4](#) ([Figs 1-5](#)).

## Discussion

In total, 185 coronectomy sites were reviewed in this study. Approximately 55% of patients attended follow-up meetings. Other patients did not present at successive evaluation appointments. The authors pre-

sume that the patients who did not keep their appointments had a normal healing process and determined there was no need for medical evaluation.

There were 6 failures after coronectomy owing to enamel retention. Immediate postoperative radiographic imaging is mandatory to exclude this complication because clinical inspection is insufficient. In 4 of these 6 cases, after enamel retention was diagnosed, the coronectomy was repeated, which was followed by normal healing. The authors recommend performing repeat coronectomy whenever enamel retention is diagnosed and close to the diagnosis, before residual roots become infected.

After coronectomy, residual roots can migrate. The average migration distances after 6 and 12 months were 2.2 and 3.2 mm, respectively. These measurements are supported by those in other studies.<sup>3,7,10,11</sup> Statistically meaningful differences in measurements were found between the 6- and 12-month follow-up meetings. Hence, unless the patient becomes symptomatic, the authors regard a 12-month postoperative evaluation sufficient. The authors also observed that the potential of migration is greater in younger versus older patients.

**Table 1. PATIENTS' DEMOGRAPHIC CHARACTERISTICS**

Men, n (%)	110 (59.5)
Women, n (%)	75 (40.5)
Age (yr), mean (SD)	27.6 (11.03)
Age (yr), median	23

Abbreviation: SD, standard deviation.

*Frenkel, Givol, and Shosbani. Coronectomy of Mandibular Third Molar. J Oral Maxillofac Surg 2015.*

**Table 2. ASSESSMENT AT FIRST, SECOND, AND THIRD EVALUATIONS**

Parameter	First Evaluation	Second Evaluation	Third Evaluation
Time for evaluation (mo), average (SD)	4.2 (2.2)	6.1 (1.4)	12.9 (2.4)
Total teeth evaluated, n	102	64	34
Good healing, n (%)	56 (56)	59 (92)	32 (94)
Pain, n (%)	16 (16)	3 (5)	1 (3)
Inflammatory process, n (%)	15 (15)	3 (5)	0
Pocket depth (mm), (SD)	—	4 (1.6)	3.8 (1.6)
Pocket depth >5 mm, n (%)	—	14 (21)	2 (6)
Lack of bone formation, n (%)	—	5 (9)	21 (61)
Residual root migration, n (%)	—	41 (64)	3.2 (1.2)
Residual root migration (mm), average (SD)	—	2.2 (1.04)	12.9 (2.4)
Reoperation, n	3	1	2
Repeat coronectomy, n	3	1	0
Sensory impairment, n (%)	1 (1)		

Abbreviation: SD, standard deviation.

Frenkel, Givol, and Shoshani. *Coronectomy of Mandibular Third Molar. J Oral Maxillofac Surg 2015.*

After coronectomy, residual roots can erupt into the oral cavity and become infected.<sup>10</sup> In this study, 1 case showed residual root eruption into the oral cavity after 1 year, and these residual roots were completely removed.

The incidence of IAN injury in this study was 0.5% (1 of 185). This injury was temporary and manifested as hypoesthesia. These results correlate with those in the literature.<sup>3,9</sup>

**Table 3. STATISTICALLY SIGNIFICANT DIFFERENCES BETWEEN "MIGRATION" AND "NO-MIGRATION" GROUPS BY AGE**

Parameter	"Migration" Group	"No-Migration" Group	P Value
Age (yr) at 6-mo appointment, average (SD)	24.5 (9.2)	39.6 (16.4)	<.01
Age (yr) at 12-mo appointment, average (SD)	24.5 (10.2)	37.5 (18.8)	<.01

Abbreviation: SD, standard deviation.

Frenkel, Givol, and Shoshani. *Coronectomy of Mandibular Third Molar. J Oral Maxillofac Surg 2015.*

**Table 4. SUMMARY OF CORONECTOMY FAILURE CASES**

Patient	Age (yr)	Gender	Time After Procedure	Signs	Cause of Failure	Reoperation* or Repeat Coronectomy
1	55	M	4 wk	pain, pus	enamel retention	reoperation
2	55	M	4 wk	unsatisfactory healing, pus	enamel retention	repeat coronectomy
3	22	M	4 wk	unsatisfactory healing	enamel retention	repeat coronectomy
4	47	F	4 wk	unsatisfactory healing	enamel retention	repeat coronectomy
5	20	F	6 wk	delayed healing, pain	root mobilization during procedure	reoperation
6	20	F	8 wk	inflammatory process, pain	enamel retention	reoperation
7	24	F	3.5 mo	deep pocket, pain	enamel retention	repeat coronectomy
8	24	M	5 mo	pain	unknown	reoperation
9	34	F	12 mo	pain	unknown	reoperation
10	61	F	12 mo	residual root eruption	residual root eruption	reoperation

Abbreviations: F, female; M, male.

\* Reoperation consisted of total removal of residual roots.

Frenkel, Givol, and Shoshani. *Coronectomy of Mandibular Third Molar. J Oral Maxillofac Surg 2015.*



Overall failure was 10 of 185 cases (5.4%); if only the cases that required complete removal of the residual roots are included, then the failure rate decreases to 3%.

Coronectomy is a safe procedure used to prevent IAN injury. The authors recommend immediate postoperative radiographic imaging and evaluation 12 months after surgery. They also advise repeat surgery in cases in which enamel retention is diagnosed to avoid the residual roots becoming infected. Moreover, even when radiographic signs do not imply close proximity of the roots to the IAN, but the patient is too anxious to undergo conventional extraction, coronectomy is recommended.

## References

1. Long H, Zhou Y, Liao L, et al: Coronectomy vs. total removal for third molar extraction: A systematic review. *J Dent Res* 91:659, 2012
2. Gleeson CF, Patel V, Kwok J, et al: Coronectomy practice. Paper 1. Technique and trouble-shooting. *Br J Oral Maxillofac Surg* 50: 739, 2012
3. Leung YY, Cheung LK: Safety of coronectomy versus excision of wisdom teeth: A randomized controlled trial. *Oral Surg Oral Med Oral Pathol Oral Radiol Endod* 108:821, 2009
4. Rood JP, Shehab BA: The radiological prediction of inferior alveolar nerve injury during third molar surgery. *Br J Oral Maxillofac Surg* 28:20, 1990
5. Matzen L, Christensen J, Hintze H, et al: Influence of cone beam CT on treatment plan before surgical intervention of mandibular third molars and impact of radiographic factors on deciding on coronectomy vs surgical removal. *Dentomaxillofac Radiol* 42: 98870341, 2013
6. Knutsson K, Lysell L, Rohlin M: Postoperative status after partial removal of mandibular third molar. *Swed Dent J* 13:15, 1989
7. Pogrel MA, Lee JS, Muff DF: Coronectomy: A technique to protect the inferior alveolar nerve. *J Oral Maxillofac Surg* 62: 1447, 2004
8. Monaco G, de Santis G, Gatto MR, et al: Coronectomy: A surgical option for impacted third molars in close proximity to the inferior alveolar nerve. *J Am Dent Assoc* 143:363, 2012
9. Patel V, Gleeson CF, Kwok J, et al: Coronectomy practice. Paper 2. Complication and long term management. *Br J Oral Maxillofac Surg* 51:347, 2013
10. Goto S, Kurita K, Kuroiwa Y, et al: Clinical and dental computed tomographic evaluation 1 year after coronectomy. *J Oral Maxillofac Surg* 70:1023, 2012
11. Leung YY, Cheung LK: Coronectomy of lower third molar is safe within the first 3 years. *J Oral Maxillofac Surg* 70:1515, 2012